

Original Article

Comparison of phaco-nucleotomy techniques in management of pseudoexfoliation syndrome

Narendra P Datti*, Kanthamani K, Prashanth K, Tejal S J, Prarthana Karnath

Department of Ophthalmology, Sri Devaraj Urs Medical College, Kolar, Karnataka, India.

Received: 21st March-2013 Accepted: 14th July-2013 Published: 30th September-2013

Abstract

Background: Pseudoexfoliation syndrome is a common clinically important systemic condition characterized by the pathological production and accumulation of an abnormal fibrillar extracellular material in many intraocular and extraocular tissues. Many studies have shown that pseudoexfoliation syndrome patients with higher rates of intraoperative complications during cataract surgery compared to the patients without it. The present study is undertaken to compare phaco chop and divide and conquer techniques of phacoemulsification, in the management of pseudoexfoliation syndrome in terms of intraoperative complications. **Methods:** It is a hospital based prospective study of 90 patients with cataract and pseudoexfoliation syndrome attending R. L. Jalappa Hospital and Research Centre, Tamaka, Kolar. **Results:** The average age of patients in the study was 61.7 years with a male preponderance with equal incidence of unilateral and bilateral involvement. 97.8% of the patients were implanted with intraocular lens after the employment of various surgical modifications. Intraoperative complications noted in vertical chopping technique was only pupil constriction in 6.7%, whereas in horizontal chopping 13.3% had pupil constriction, 6.7% had difficulty in chopping, 3.3% had zonular dehiscence and 3.3% had PC Rent. In divide and conquer technique 16.7% had pupil constriction, 10% had difficulty in trenching, 3.3% had PC Rent. **Conclusion:** Though phacoemulsification surgery in eyes with pseudoexfoliation syndrome is associated with intraoperative complications, vertical chopping technique scores over horizontal chopping and divide and conquer technique of phacoemulsification with good surgical outcome because of less complications.

Key words: Mydriasis, Posterior-capsular rent, Pseudoexfoliation syndrome, Zonular dehiscence.

Introduction

Pseudoexfoliation syndrome is an age related disease and is frequently associated with cataract⁽²⁾. It is characterized by pathological production and accumulation of an abnormal fibrillar extracellular material in many intraocular and extraocular tissues. Pseudoexfoliation syndrome in the eye is characterized clinically by small white deposits of material in the anterior segment, most commonly in the pupillary border and the anterior lens capsule. Patients with pseudoexfoliation syndrome have a significantly greater risk of a variety of complications during cataract surgery⁽³⁾. Phacoemulsification is the preferred method of cataract surgery in these patients. The purpose of this study is to compare phaco-chop, and divide and conquer techniques of phacoemulsification in pseudoexfoliation syndrome in terms of intraoperative complications.

Materials and methods

A prospective study, with a total number of 90 patients suffering from cataract with pseudoexfoliation syndrome satisfying the inclusion and exclusion criteria were studied at R. L. Jalappa Hospital and Research Centre, Tamaka, Kolar, attached to Sri Devaraj Urs Medical College between November 2009 and May 2011. These patients were divided into two groups; group A- vertical chop (30 patients) and horizontal chop (30 patients) and group B-divide and conquer (30 patients). The inclusion criteria for this study were patients undergoing phacoemulsification cataract surgery with pseudoexfoliation syndrome, patients documented to have pseudoexfoliation material on the pupillary margin and on the anterior surface of the lens capsule, and patients with senile (immature, mature and hypermature) cataracts with pseudoexfoliation syndrome.

*Corresponding Author

Narendra P Datti, Professor, Department of Ophthalmology, SDUMC, Kolar, Karnataka, India.

E mail : npdatti@gmail.com

Quick access Code



The patients excluded from our study were those with traumatic cataracts, complicated cataracts, subluxated lens without pseudoexfoliation syndrome, senile (immature, mature and hypermature) cataracts without pseudoexfoliation syndrome, ocular hypertensives and glaucoma patients.

Preoperatively, the parameters assessed were uncorrected visual acuity (UCVA) using Snellen's chart and near vision chart, best corrected visual acuity (BCVA), refraction, external ocular examination, slit lamp bio microscopy, pre-dilatation pupil size measured with the scale on the slit lamp bio microscope, fundus examination, B-scan evaluation, tonometry using Goldmann applanation tonometer and gonioscopy with Goldmann three mirror lens-any pseudoexfoliation material in the angle of the anterior chamber was noted. Lacrimal patency test, keratometry, A-scan was also done and IOL power was calculated using SRK-II formula. Urine examination for albumin and sugar was done. All patients were given systemic antibiotics (tablet ciprofloxacin 500mg b.d.) on the preoperative day. On the day of surgery, pupils were adequately dilated using 0.8% tropicamide and 5% or 10% phenylephrine eye drops every 10 minutes, one hour prior to surgery. To sustain pupillary dilatation anti-prostaglandin eye drops, flurbiprofen was instilled three times, one day before surgery and half hourly for two hours immediately before surgery. Peribulbar anaesthetic block was given using 2% xylocaine with adrenaline mixed with 1500 units of hyaluronidase. The eye to be operated was painted, draped and prepared for surgery under aseptic precautions. The surgical area of the eye was exposed using Universal wire speculum. Superior rectus (bridle) suture was passed to fix the eye in downward gaze. Based on the degree of mydriasis, the pupil was stretched mechanically or sphincterectomies were done (depending on surgeon's discretion). Synechiolysis was done, where necessary. Standard phacoemulsification procedure was followed. The phacoemulsification was performed via different nucleotomy techniques as shown in Figure1.

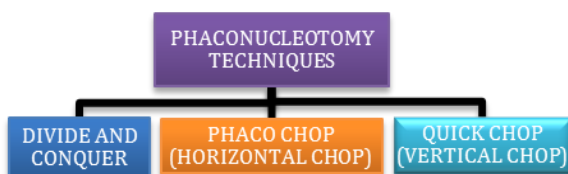


Fig: 1 - Various Phaconucleotomy Techniques

Divide and Conquer Technique: Four basic steps were incorporated in divide and conquer technique- deep sculpting until a fracture was possible, nucleofractis of the nuclear rim and posterior plate of the nucleus, fracturing again and breaking away a wedge-shaped section of nuclear material for emulsification, and rotation or repositioning of the nucleus for further fracturing and emulsification. Phaco chop (Horizontal chop): the phacoemulsification tip was initially buried in the direction of the centre of the nucleus. The lens nucleus was held in position using relatively high vacuum, while the chopping instrument was passed under the distal edge of the anterior capsulotomy and the lens was cleaved. The phaco tip and chopper were then separated laterally, breaking the nucleus into two pieces. The same procedure was repeated and the nucleus was broken into four or more pieces depending on the density of the lens.

Quick chop (vertical chop): quick chop is a variant of the phaco chop technique in which the chopper is not passed horizontally around the lens equator, but rather enters the nucleus vertically near the centre of the lens and the nucleus is held in place with vacuum. Next, the chopper was placed slightly in front of the phaco tip, and the chopper tip was embedded as deeply as possible into the lens. Force is applied laterally and downward with the chopper to split the lens into two halves. The benefits of this procedure are the good visualization of the chopper throughout and the avoidance of proximity to the capsular bag, resulting in increased safety. Cortical matter was removed by irrigation and aspiration. Intraoperative complications in all the three nucleotomy techniques performed were noted. Rigid posterior chamber intraocular lens was placed in the capsular bag after extending the incision. The viscoelastic was cleared from the anterior chamber. Subconjunctival gentamycin and dexamethasone 0.5cc were given at the end of the procedure. Pad and bandage were applied. Postoperatively, all patients received a course of topical antibiotic and steroid eye drops second hourly for a week, followed by a tapering dose for 6 weeks along with flurbiprofen eye drops 0.03% three times a day for 4 weeks. Systemic antibiotic tablet ciprofloxacin 500mg was given for 5 days postoperatively. Tablet diclofenac was given in case the patient complained of pain.

Results

As shown in table 1, there were 8 (8.8%) patients of age group 48-50 years, 36 (41%) patients of age group 51-60 years and 42 (46%) patients above the age of 70 years. The average age of the patients was 61 years and about 46 (51%) of patients were above 60 years of age.

AGE IN YEARS	GROUP A		GROUP B	
	No.	%	No.	%
45-50	6	10.0	2	6.7
51-60	24	40.0	12	40.0
61-70	26	43.3	16	53.3
71-80	3	5.0	0	0.0
81-90	1	1.7	0	0.0
TOTAL	60	100.0	30	100.0
Mean ± SD	61.47 ± 7.11		61.17 ± 5.34	

Table:1 – Comparison of Age Distribution

VARIABLES	GROUP A		GROUP B	P VALUE
	Vertical chop (n=30)	Horizontal chop (n=30)	(n=30)	
Age in years	60.20±5.70	62.73±9.07	61.17±5.34	0.362
Gender M/F	17:13	11:19	23:7	0.008
Pupil Shape	(6.7%)	1 (3.3%)	0	
Round	28 (93.3%)	29 (96.7%)	30 (100.0%)	0.770
Irregular	1 (3.3%)	1 (3.35%)	0	

Table:2 – Comparison of Basic, Clinical Variables and sex determination in Three Groups of Patients

Pupil Reaction	GROUP A		GROUP B
	VERTICAL CHOP	HORIZONTAL CHOP	
Normal	29 (96.7%)	29 (96.7%)	30 (100.0%)
SR	1 (3.3%)	1 (3.3%)	0

Table:3 – Basic Pupillary Reaction in Three Groups

As shown in table 2, 95% in group A and 100% in group B were irregular in shape and 96.7% in group A and 100% in group B, pupils were normally reacting to light. 51 (56.6%) patients were males and 39 (43%) patients were females. As shown in table 3, 29 (96.7%) patients in group A and 30 (100%) patients in group B had normal pupillary reaction and 1 (3.3%) patients in groups A and B had sluggish reaction. In the present study, 81% had

COMPLICATIONS	GROUP A		GROUP B	P VALUE
	VERTICAL CHOP (n=30)	HORIZONTAL CHOP (n=30)	(n=30)	
Pupillary constriction	2 (6.7%)	4 (13.3%)	5 (16.7%)	0.524
Difficulty in trenching	0	0	3 (10.0%)	0.104
Difficulty in chopping	0	2 (6.7%)	0	0.326
Iridodonesis	0	0	0	-
Posterior capsule rent	0	1 (3.3%)	1 (3.3%)	1.000
Vitreous loss	0	0	0	-
Nucleus drop	0	0	0	-
Zonular dehiscence	0	1 (3.3%)	0	1.000
Others	0	0	0	-

Table:4 – Comparison of Complications in Three Groups of Patients

As per table 4, in patients who underwent vertical chopping technique 2 (6.7%) had pupil constriction; in patients who underwent horizontal chopping, 4 (13.3%) had pupil constriction, 2 (6.7%) had difficulty in chopping, 1 (3.3%) had zonular dehiscence and 1 (3.3%) and Posterior Capsule Rent. Amongst patients who underwent divide and conquer technique 5 (16.7%) had pupil constriction, 3 (10%) had difficulty in trenching, 1 (3.3%) had Posterior Capsule Rent.

Results

The present study consisted of 90 patients with pseudoexfoliation syndrome who underwent phacoemulsification surgery in R. L. Jalappa Hospital and Research Centre, Tamaka, Kolar attached to Sri Devaraj Urs Medical College between November 2009 and May 2011. In this study, 51% of the patients are in the age group of 60-90 years which is in concurrence with other similar studies. Studies regarding the sex distribution of pseudoexfoliation syndrome are conflicting. Women have predominated in some series while other studies have found equal or greater prevalence in men. In this study, 45 (50%) patients had clinical bilateral involvement of pseudoexfoliation syndrome and 45 (50%) had unilateral involvement. A review of literature comparing the frequency of monocular versus binocular involvement in various series is not conclusive. Many series have reported bilateral involvement to be more

common with ratios as high as 3:1 while other studies have reported unilateral involvement to predominate again with ratios as high as 3:1.

Discussion

In the present study, 51% of the patients are in the age group of 60-90 years which is in concurrence with other similar studies. Studies regarding the sex distribution of pseudoexfoliation syndrome are conflicting. Women have predominated in some series while other studies have found equal or greater prevalence in men.

In this study, 45 (50%) patients had clinical bilateral involvement of pseudoexfoliation syndrome and 45 (50%) had unilateral involvement. A review of literature comparing the frequency of monocular versus binocular involvement in various series is not conclusive. Many series have reported bilateral involvement to be more common with ratios as high as 3:1 while other studies have reported unilateral involvement to predominate again with ratios as high as 3:1. Hammer, Schlotzer-Schrehardt, Naumann carried out an ultra structural study of the contralateral eye in 5 pairs of donor eyes with unilateral pseudoexfoliation syndrome^[1]. They concluded that basically, pseudoexfoliation syndrome is a bilateral disease with clinically marked asymmetric manifestations. Freyler H, Radax U noted pupillary dilatation less than 4 mm in 19 of 32 patients with pseudoexfoliation syndrome who underwent cataract surgery^[2]. Stanila A also noted an increased incidence of insufficient pupil dilatation in the 10 patients with pseudoexfoliation syndrome undergoing cataract surgery in their study^[3]. In the present study, 20% had pigment dispersion after mydriasis.

Selandet al have reported a higher incidence of nuclear cataract in eyes with pseudoexfoliation syndrome with fewer cortical cataracts, as was observed in our study^[4]. Scrolloliet al have found that Pseudoexfoliation patients were five times more likely to develop intraoperative complications during cataract surgery compared to patients without the condition^[5]. Freyler H, Radax U found 26 of their 36 patients with pseudoexfoliation syndrome undergoing ECCE to have intraoperative complications such as zonular dehiscence, posterior capsular rent and vitreous loss^[2]. Stanila also reported an increased incidence of posterior capsular rent and vitreous loss in their study of 10 eyes with pseudoexfoliation syndrome undergoing ECCE^[3]. Kuchleat al found 6.9% of their 11 patients to have intraoperative complication namely- zonular dehiscence and vitreous loss^[6]. Zonular fragility in pseudoexfoliation syndrome increases the risk of lens dislocation, zonular dehiscence and vitreous loss up to ten times.

Lumme P, Laatikainen L found the incidence of vitreous loss to be fourfold more in eyes with pseudoexfoliation syndrome and posterior capsular rent to be tenfold higher in eyes with pseudoexfoliation syndrome^[7]. Avramides S, Travamides P, Sakkias G found the incidence of posterior capsular rent and vitreous loss to be 10.4% and 7.14% respectively in this study of 84 patients with pseudoexfoliation syndrome undergoing cataract surgery^[8]. In our study, 13 (14.44%) underwent synechiolysis, 23 (25.55%) patients underwent sphincterotomy and 10 (11.11%) patients underwent both sphincterotomy and synechiolysis. Alfaiteet al in their study of 31 eyes of pseudoexfoliation syndrome undergoing ECCE noted a statistically significant increase (p value < 0.01) in the need to perform sphincterotomies^[3]. Kuchleat al noted 3.4% of their 76 patients to require surgical synechiolysis and/or mechanical dilatation of pupil intraoperatively^[6].

Vickie Lee and Anthony Maloof advocated that small pupils could be enlarged by prosthetic and non prosthetic methods. Non prosthetic techniques include visco-mydriasis, manual iris stretching and iris micro- sphincterotomies^[9]. Prosthetic techniques include iris hooks and use of pupil expansion devices. Patients with pseudoexfoliation syndrome and cataract for phacoemulsification surgery have to be carefully examined for zonular weakness, insufficient mydriasis, intraocular pressure, subluxation or dislocation of cataractous lens because these preoperative factors have bearing on the intraoperative complications.

Inadequate mydriasis is one of the major preoperative factors in eyes with pseudoexfoliation syndrome which has a bearing on the intraoperative complications like posterior capsular rent and vitreous loss. Adequate surgical modifications such as sphincterotomy and/or synechiolysis, pupil stretching, use of iris hooks in these eyes with inadequate mydriasis reduce the intraoperative complications. We found that chopping techniques are best suited for pseudoexfoliation and amongst these vertical chopping scores over horizontal chopping as it has fewer complications because of the good visualization of the chopper throughout, the avoidance of proximity to the capsular bag and decreased pressure on the zonules, resulting in increased safety.

References

1. Hammer T, Schlötzer-Schrehardt U, Naumann GO. Unilateral or asymmetric pseudoexfoliation syndrome? An ultrastructural study. *Arch. Ophthalmol.* 2001 Jul;119(7):1023-31.

2. Freyler H, Radax U. [Pseudoexfoliation syndrome-a risk factor in modern cataract surgery?]. *Klin. Monatsblätter Für Augenheilkd.* 1994 Nov;205(5):275-79.
3. Stanila A. [Extracapsular extraction of the crystal line lens]. *Oftalmol. Buchar. Rom.* 1990. 1996 Sep;40(3):264-73.
4. Seland JH, Chylack LT Jr. Cataracts in the exfoliation syndrome (fibrillogenesis epitheliocapsularis). *Trans. Ophthalmol. Soc. U. K.* 1982;102 Pt 3:375-9.
5. Scorolli L, Scorolli L, Campos EC, Bassein L, Meduri RA. Pseudoexfoliation syndrome: a cohort study on intraoperative complications in cataract surgery. *Ophthalmol. J. Int. Ophtalmol. Int. J. Ophthalmol. Z. Für Augenheilkd.* 1998;212(4):278-80.
6. Kuchle M, Viestenz A, Martus P, Händel A, Jünnemann A, Naumann GO. Anterior chamber depth and complications during cataract surgery in eyes with pseudoexfoliation syndrome. *Am. J. Ophthalmol.* 2000 Mar;129(3):281-5.
7. Lumme P, Laatikainen L. Exfoliation syndrome and cataract extraction. *Am. J. Ophthalmol.* 1993 Jul 15;116(1):51-5.
8. Avramides S, Traianidis P, Sakkias G. Cataract surgery and lens implantation in eyes with exfoliation syndrome. *J. Cataract Refract. Surg.* 1997 May;23(4):583-7.
9. Lee V, Maloof A. Cataract surgery in pseudoexfoliation syndrome. *Comp. Ophthalmol. Update.* 2002 Jan; 3(1): 169-171.