

## Case Report

# Generalized Lichen Nitidus treated With Tacrolimus

Rajashekar T S, Rajendra Okade  
*Department of Dermatology,  
Sri Devaraj Urs Medical College, Kolar*

### ABSTRACT

*Lichen nitidus is a rare chronic condition of unknown etiology, usually asymptomatic, characterized by the presence of multiple, tiny, discrete, shiny, flesh colored, flat papules 2-3 mm in diameter. Lichen nitidus classically involves the genitalia, upper extremities, chest and abdomen; in rare instances, it may become generalized. We report a case of generalized lichen nitidus treated with tacrolimus.*

### INTRODUCTION

Lichen nitidus is an uncommon chronic condition of unknown etiology, usually asymptomatic, characterized by the presence of multiple, tiny, discrete, shiny, flesh coloured, flat papules 2-3 mm in diameter. Lichen nitidus classically involves the genitalia, upper extremities, chest and abdomen; in rare instances, it may become generalized. Many rare clinical variants of lichen nitidus have been described, generalized form is one of them.<sup>[1,2,3]</sup> We report a case of generalized lichen nitidus treated with tacrolimus.

### CASE REPORT

A seven year old male child presented with non-pruritic, generalized cutaneous eruption of six months duration. Cutaneous

examination revealed multiple, asymptomatic, discrete, 1-2 mm, skin-coloured, shiny, flat papules over chest, abdomen, back, nape of the neck and upper extremities (Fig-1). Multiple foci of koebnerization were seen over trunk (Fig-2). Oral mucosa, nails, palms and soles were spared. The child did not have any associated systemic complaints. The laboratory tests were normal. A skin biopsy was performed and was consistent with that of lichen nitidus showing granulomatous lymphohistiocytic infiltrate in an expanded dermal papilla with thinning of overlying epidermis and downward extension of the rete ridges at the lateral margin of the infiltrate, producing a typical "claw clutching a ball" picture (Fig-3). Initially patient was treated with topical mometasone cream for a period of 8 weeks with no clinical improvement and was hence considered for NB-UVB therapy for which the patient was not compliant.

### Corresponding Author:

**Dr. Rajashekar T.S**

Associate Professor

Dept. of Dermatology


RLJH&RC,

Tamaka, Kolar

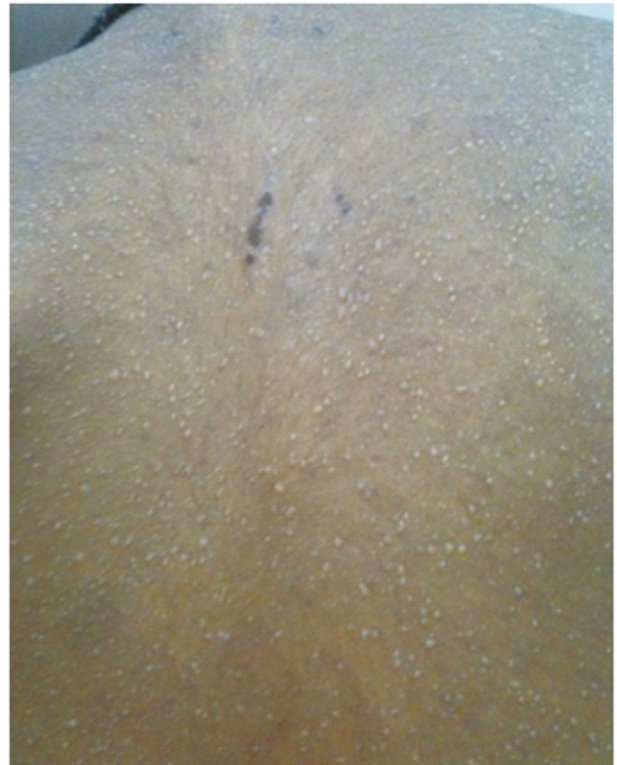Email: yeshits@rediffmail.com

### DISCUSSION

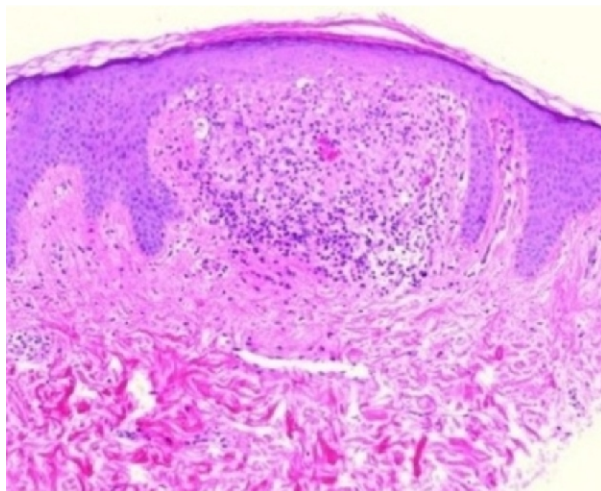
Multiple clinical variants of lichen nitidus have been described, including keratodermic, vesicular, hemorrhagic, purpuric,



**Fig.1: Multiple, skin colored, flat papules over chest and abdomen**



**Fig.2: Numerous flat papules with multiple foci of koebnerization seen on back**



**Fig.3: Granulomatous lymphohistiocytic infiltrate in an expanded dermal papilla seen**

perforating, palmoplantar and generalized forms.<sup>[4]</sup> The disorder is most often localized and only a few cases of generalized lichen nitidus have been reported.<sup>[5]</sup> Generalized lichen nitidus is a rare subtype of lichen nitidus characterized by multiple, skin-colored, shiny, dome-shaped papules occurring over the entire body.<sup>[6]</sup>

Lichen nitidus is usually asymptomatic and resolves without any sequelae, hence no treatment is required in most cases. However, the clinical course of generalized lichen nitidus is unpredictable with majority of patients experiencing spontaneous resolution several years after the onset of disease. Systemic and topical corticosteroids, dinitrochlorobenzene, diphenylcyclopropenone immunotherapy, astemizole, itraconazole, isoniazid, psoralens and ultraviolet A (PUVA) and narrow band ultraviolet B (NB-UVB) phototherapy have all been tried in its treatment, with PUVA, NB-UVB and astemizole being especially useful for generalized forms.<sup>[2]</sup> Treatment of lichen nitidus with tacrolimus 0.1 percent and generalized variant with pimecrolimus cream have been reported.<sup>[4,7]</sup> The topical calcineurin inhibitors tacrolimus and pimecrolimus have an effect on various cells of the cutaneous immune

system, specifically on T cells, by inhibiting the phosphatase calcineurin and preventing the transcription of proinflammatory cytokines.<sup>[8]</sup>

We report a case of generalized lichen nitidus that improved but did not completely clear with application of tacrolimus 0.03% ointment for three months.

## REFERENCES

1. Vijaya B, Manjunath GV. Perforating lichen nitidus. *Indian J Pathol Microbiol* 2010;53:162-3.
2. Mehta V, Balachandran C. Generalized lichen nitidus in childhood. *Indian J Dermatol* 2008;53:221-2.
3. Park SH, Kim SW, Noh TW, Hong KC, Kang YS, Lee UH, et al. A case of palmar lichen nitidus presenting as a clinical feature of pompholyx.

*Ann Dermatol* 2010;22:235-7.

4. Farshi S, Mansouri P. Generalized lichen nitidus successfully treated with pimecrolimus 1 percent cream. *Dermatol Online J* 2011;17:11.
5. Soroush V, Gurevitch AW, Peng SK. Generalized lichen nitidus: case report and literature review. *Cutis* 1999; 64:135-6.
6. Park JH, Choi YL, Kim WS, Lee DY, Yang JM, Lee ES, et al. Treatment of generalized lichen nitidus with narrowband ultraviolet B. *J Am Acad Dermatol* 2006;54:545-6.
7. Dobbs CR, Murphy SJ. Lichen nitidus treated with topical tacrolimus. *J Drugs Dermatol*. 2004 Nov-Dec;3(6):683-4.
8. Breuer K, Werfel T, Kapp A. Safety and efficacy of topical calcineurin inhibitors in the treatment of childhood atopic dermatitis. *Am J Clin Dermatol*. 2005;6(2):65-77.

**Source of Support: Nil    Conflict of Interest: Nil**