

## Case Report

# A Rare Surgical Tumor of Mesenteric Paraganglioma Presenting As A Fibroid Uterus

Harshini V, Bharathi H R<sup>1</sup>, Shameem<sup>1</sup>, Nayak S R<sup>1</sup>, Nirupama<sup>2</sup>

*Department of Obstetrics and Gynaecology,*

*Sri Devaraj Urs Medicial College, Kolar*

*Department of Obstetrics and Gynaecology*

*Manipal University, Manipal<sup>1</sup>*

*Departments of Pathology,*

*Manipal University, Manipal<sup>2</sup>*

### ABSTRACT

*Paragangliomas are rare tumors originating from the parenchymal cells of paraganglia. In adults the adrenal medulla is the largest paraganglion and paragangliomas most frequently occur in the adrenal medulla. We report a rare case of a solitary primary paraganglioma arising in the mesentery, found in a 38 yr old woman who presented with complaints of infertility dysmenorrhoea, mass per abdomen, abdominal distension since 6 months. Clinical examination and ultrasound abdomen suggested multiple fibroids. Exploratory laparotomy revealed a large mesenteric cyst The histopathology and immunohistochemistry confirmed the diagnosis of mesenteric paraganglioma.*

**Key words :**Paraganglioma, Fibroid

### CASE REPORT:

A 38 yr old, nulliparous lady, presented with complaints of dysmenorrhoea, mass per abdomen, abdominal distension since 6 months. The history of spasmodic dysmenorrhoea since 6 months with no menstrual irregularity and mass felt in the lower abdomen, 6 months back, gradually increasing to present size associated with difficulty in

micturition were elicited. On per abdomen examination 12\*7 cm pelvic mass in left lumbar region extending till hypochondrium, left iliac region, limited mobility, moves with respiration, firm consistency. On per vaginum examination- mass confirmed of 18-20wk size uterine size could not be made out; uterus measured as 10cm on passing uterine sound through the os, forniceal fullness was present. On per rectal examination, rectal mucosa was not involved and mass was felt in the pelvis ultra sound abdomen revealed multiple intra mural fibroids, and also hypoechoic mass with calcification cystic component superior to uterus suggesting pedunculated fibroid. On exploratory

---

### Corresponding Author:

**Dr. V. Harshini,**

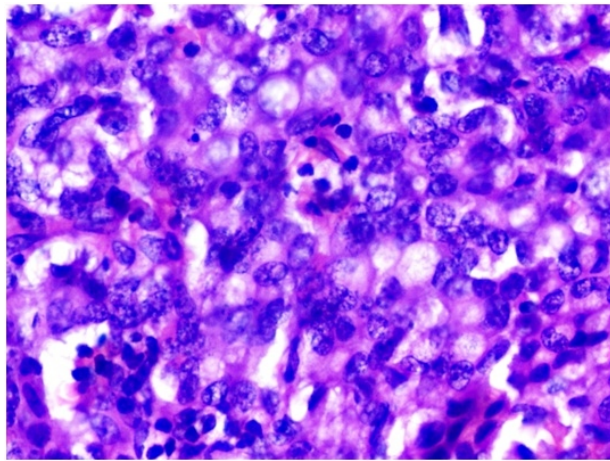
14-189, Khadar Meeran Street,

Chittoor- 517001

Mobile: +919986356016

Email ID: vharshini84@gmail.com

laparotomy, mesenteric cyst of 20\*15 cm in left lumbar region in the mesentery supplying small intestines was identified, During excision of cyst, whitish fluid had spilled from ruptured areas, ischaemic bowel of 8-10cm resected and end to end anastomosis was done. The histopathological features [fig 1] of small round cells (chief cells) arranged in discrete cohesive lobules (zellballen), peripherally encircled by spindle cells with vascular stroma confirmed diagnosis of solitary, mesenteric, paraganglioma and immunohistochemistry confirmed the diagnosis as the tumor was positive for Synaptophysin, chromogranin, S-100 markers. The patient had an uneventful post operative in the hospital and was discharged on tenth post operative day, was followed up till 1 year and was asymptomatic.



**Fig 1:Microscopic features of paraganglioma**

## **DISCUSSION :**

The parenchymal cells of the paraganglia and other elements of the autonomic nervous system arise from neural crest cells. They are derived from the neuroblastic anlage associated with the dorsal roots of vertebral somites or primitive cells associated with cranial nerve

ganglia.<sup>[1]</sup> Paragangliomas are rare tumors originating from the parenchymal cells of paraganglia. Approximately 5-10 % of sporadic paragangliomas occur at extra-adrenal sites, including anywhere from the upper neck to the pelvis.<sup>[2]</sup> In the fetus, paraganglionic tissue is derived from pheochromoblasts, the largest concentration present at a level extending from either the root of the inferior mesenteric artery or the renal artery to the aortic bifurcation, known as the organ(s) of Zuckerkandl. The fetal adrenal gland is composed primarily of neuroblasts, with an inconspicuous amount of pheochromoblasts. In contrast, in the adult, the mature adrenal medulla replaces the involuted organ(s) of Zuckerkandl to form the largest collection of paraganglionic tissue. Thus, neoplasms arising from paraganglia occur most frequently in the adrenal medulla, where they are known as pheochromocytoma. The remaining small amount of normal paraganglionic tissue occurs in extra-adrenal sites extending from the upper cervical region to the pelvis, paralleling the autonomic nervous system. Neoplasms derived from paraganglionic tissue in these sites are known as paragangliomas and arise mostly from remnants of the organ(s) of Zuckerkandl. Small amounts of paraganglionic tissue have been described in usual sites outside the conventional distribution, such as in the interatrial septum of the heart, liver hilus, gallbladder, urinary bladder, prostatic capsule, and mesenteric vessels, potentially capable of giving rise to paragangliomas in these unusual sites.<sup>[3]</sup> The tumor cells show positivity for chromogranin A, synaptophysin, CD 56, PGP 9.5. Immunostaining S-100 identifies sustentacular cells. About 97% are benign and

cured by surgical removal; the remaining 3% are malignant because they are able to produce distant metastases. The main treatment modalities are surgery, embolization<sup>[4]</sup> and radiotherapy.<sup>[5]</sup>

There are no clear data regarding the survival of patients with localized (apparently benign) disease or regional disease. Although patients with localized (apparently benign) disease should experience an overall survival approaching that of age-matched disease-free individuals, 6.5% to 16.5% of these patients will develop a recurrence, usually 5 to 15 years after initial surgery. Approximately 50% of patients with recurrent disease experience distant metastasis.<sup>[6]</sup> The 5-year survival in the setting of metastatic disease (whether identified at the time of initial diagnosis or identified postoperatively as recurrent disease) is 40% to 45%.<sup>[7]</sup>

#### **REFERENCES :**

1. Jaffer S, Harpaz N: Mesenteric paraganglioma: a case report and review of the literature. *Arch Pathol Lab Med* 2002;126: 362-36.
2. Besana Ciani I, Boni L, Dionigi G, Benevento

A, Dionigi R. Outcome and long-term results of surgical resection for gastrointestinal stromal tumors (GIST). *Scand J Surg* 2003;92:195-99.

3. Smetana HWF. Scott. Malignant tumors of non chromaffinparaganglia. *Mil Surg* 1951;109:30.

4. Carlsen CS, Godballe C, Krogdahl AS, Edal AL. "Malignant vagal paraganglioma: report of a case treated with embolization and surgery". *Auris, nasus, larynx* 2003;30: 443-46.

5. Pitiakoudis M, Koukourakis M, Tsaroucha A, Manavis J, Polychronidis A, Simopoulos C. Malignant retroperitoneal paraganglioma treated with concurrent radiotherapy and chemotherapy. *Clinical oncology* 2004;16: 580-81.

6. Amar L, Servais A, Gimenez-Roqueplo AP, et al.: Year of diagnosis, features at presentation, and risk of recurrence in patients with pheochromocytoma or secreting paraganglioma. *J Clin Endocrinol Metab* 2005;90: 2110-16.

7. Averbuch SD, Steakley CS, Young RC, et al.: Malignant pheochromocytoma: effective treatment with a combination of cyclophosphamide, vincristine, and dacarbazine. *Ann Intern Med* 1988; 109: 867-73.

**Source of Support: Nil Conflict of Interest: Nil**