

Case Report

Leptospirosis -A Case Report of a Patient with Unusual Pulmonary Involvement

Krishnappa J, Susheela C, Beena PM¹, Dhananjaya C.D

Department of Pediatrics and Microbiology¹, Sri Devaraj Urs Medical College, Kolar

ABSTRACT

Leptospirosis is prevalent worldwide and endemic in many areas of South India including Kolar district, Karantaka. It has a broad spectrum of clinical manifestations varying from inapparent Influenza like illness to fulminant fatal disease with hepatorenal dysfunction, myocarditis and pulmonary alveolar hemorrhage with respiratory distress. We report a case presented with high degree fever and puffiness of face of 8 days duration and respiratory distress of 2days duration. Examination revealed hepatosplenomegaly and signs of respiratory failure. Investigation revealed thrombocytopenia, abnormal liver function test and positive for antileptospira antibody (IgM). This patient expired 6 hours after admission. Leptospirosis is a grossly underdiagnosed disease in our country due lack of awareness, protean manifestations and inadequate diagnostic facilities in many areas, Early diagnosis and appropriate treatment can prevent fatal outcome.

Keywords: *Leptospirosis, pulmonary, manifestation.*

INTRODUCTION

Leptospirosis, a worldwide zoonotic disease caused by *Leptospira interrogans* complex.^[1, 2] Adolf Weil described leptospirosis in 1886. *Leptospira* are cork screw shaped bacteria belonging to spirochetes genus *Leptospira*. Seroconversion (IgM) may occur as early as 5 to 7 days after onset of infection. Leptospirosis may be underdiagnosed because of non-specific manifestations. Fatality rate ranges from 5% to 30%, the cause of death is

mostly due to cardiorespiratory failure, renal failure, and hemorrhage and hepatic failure.^[1,2]

Humans are accidental hosts and become infected through contact with water and soil contaminated by the urine of infected animals such as rodents, dogs, pigs, cattle and rabbits.^[1,2] The outbreaks of leptospirosis have been reported from coastal districts of Gujarat, Karnataka, Maharashtra, Andhra Pradesh, Kerala, Tamil Nadu, Andaman, Goa and Orissa.^[3] The emergence of epidemics of leptospirosis has occurred proportionately to the alteration in the ecosystem. The factors which are responsible for the emergence of leptospirosis are animal reservoirs, change in the ecosystem, water logging, drainage congestion due to heavy rainfall, developmental activities like road widening, canal work, soil salinisation, and variations in soil temperature.^[4, 5] Exposure

Corresponding Author:

Dr. Krishnappa .J

Assoc. Professor,

Department of Paediatrics,

Sri Devaraj Urs Medical College,

Tamaka, Kolar.

Mob: 9448587233

E-mail: drjkgowda@gmail.com

of abraded skin and mucus membrane to leptospira can lead to infection. Direct transmission of leptospira is rare.^[6] Males suffer more frequently than females and are more common in older children. Leptospira occurs commonly during rainy season (June to September). Agricultural workers, livestock handlers, sewage workers are more prone for leptospira infection.

CASE REPORT

An eight year old female child from agricultural family and poor socio economic background was admitted with history of fever with chills and puffiness of face of 8 days duration. Vomiting, pain abdomen and breathlessness of 2 days duration. There was no history of rashes, oliguria, or bleeding manifestations.

This child was admitted to two different hospitals for above complaints and (unsuccessfully) treated with Co-amoxycylav, Amikicin and IV fluids. On examination, child was irritable, dyspnoic, vital parameters were abnormal ie febrile, pulse rate-140/min, all peripheral pulses were low volume. Respiratory rate was 72/min, chest indrawing was present. Blood pressure was 74/40 mm of Hg, CFT prolonged (more than 2sec). Puffiness of the face and conjunctival suffusion was present. Cyanosis was observed over lips and tongue. Respiratory examination revealed, tachypnoea, intercostal indrawing, flaring of alae nasi, bilateral crepitations and rhonchi. SPO2 was 72% at room air.

Per-abdominal examination revealed, significant hepatosplenomegaly and generalized

tenderness. Provisional diagnosis of acute respiratory distress syndrome due to Dengue haemorrhagic fever (grade III) or leptospirosis was considered and initiated emergency treatment including mechanical ventilation with settings of RR-22/min, PEEP-20 cm of H₂O, FiO₂ -0.6, I:E = 1:1. Investigations revealed, leucocytosis, thrombocytopenia (98,000/cu mm), mildly increased liver enzymes ie AST-240 U/L, ALP-280 U/L. Normal serum electrolytes and renal functions. Chest X-ray revealed-Bilateral non homogenous opacities involving both of lung fields. (fig 1) ABG done at the time of admission showed type I respiratory failure with metabolic acidosis (P_H 7.2, pO₂ 40 mm Hg, pCO₂ 30 mm Hg, HCO₃ 14 mmol/L). Antileptospira antibodies (IgM) were detected by ELISA method (Qualitative). Dengue serology was negative. After investigation child was started on Inj. crystalline penicillin 50000 IU/kg/dose 6th hourly along with supportive measures like fluid resuscitation with Ringer lactate 20ml/kg as bolus and dopamine 10 microg/min. Hypoglycemia was corrected with 2ml/kg 25% Dextrose.

In spite of above management child expired after 6 hours after admission.

DISCUSSION

Leptospirosis is being recognized as an emerging disease. Transmission is by direct or indirect contact with urine, blood, and tissue of infected animals containing virulent Leptospira.^[7] Incubation period is usually 1 to 3 weeks. Majority of leptospira cases are under diagnosed or misdiagnosed due to non-specific illness or unusual presentation.^[8]

The clinical manifestations of leptospirosis range from subclinical to potentially fatal manifestations. The disease manifests as biphasic illness, consisting initial leptospiraemic phase lasting for 3 to 7 days and an immune phase lasting for 4-30 days. On the basis of clinical features two forms of leptospirosis are described ie; anicteric and icteric leptospirosis.our patient presented with fever with chills,headache,vomiting,puffiness of face (because of vasculitis and capillary leak), pain abdomen, respiratory distress and cyanosis,This child was admitted to 2 different hospitals, but leptospirosis was not suspected because of nonspecific manifestations.

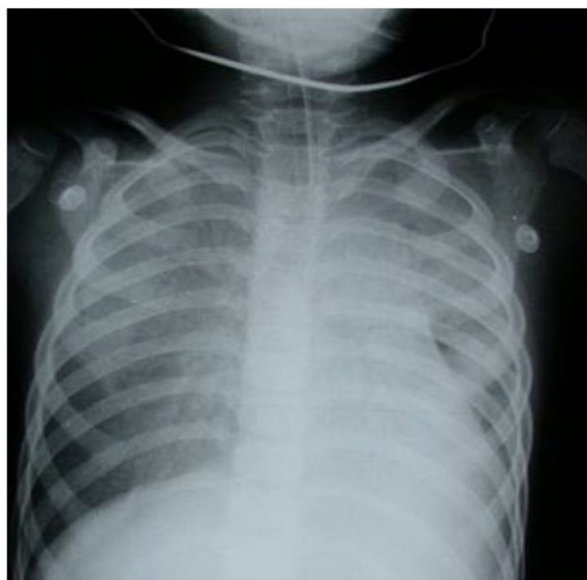


Figure - 1: X-Ray chest showing features of ARDS.

X-ray chest revealed features of ARDS (figure 1). Severe respiratory system involvement leading to respiratory failure is very rare in anicteric leptospirosis.^[8] This patient had pulmonary alveolar hemorrhage leading to ARDS and expired 6 hours after admission. This child could have been saved if treatment was initiated early. Misdiagnosis and mis

management is common for this potentially treatable condition.^[9]

Pulmonary manifestations occur in 20 to 70% of patients and many patients can progress to ARDS. ARDS is usually seen in second week of illness in severe form of leptospirosis. Our patient showed pulmonary involvement in the form of ARDS.V.Chouhan et al reported a case of severe leptospirosis involving acute renal failure, jaundice and pulmonary involvement.^[10] Severe form of leptospirosis including major hemorrhagic complications is usually associated with jaundice and renal failure.In a cohort of 26 Spanish patients 7 patients presented with hemoptysis and only 3 patients had ARDS.An ARDS requiring mechanical ventilation is associated with mortality rate as high as 30 to 60%.^[11]

Initial diagnosis of leptospirosis still remains a clinical presumptive one made in the correct epidemiological and clinical context. For early diagnosis,leptospira can directly be demonstrated in the blood by dark ground microscopy, however it is insensitive and shows false positive results. Culture of blood may be useful but requires specialized techniques.Detection of antibodies is the quickest way to confirm infection. Antibodies can be demonstrated by 5-6 days after the symptoms have developed.

The microscopic agglutination test (MAT) is accepted as the gold standard to detect genus specific antibody and it is available only in few reference centers.^[12] Lepto IgM ELISA detects the presence or absence of leptospira antibodies.it has a sensitivity of 97.29% and specificity of 99.84%. However it does not

The clinical manifestations of leptospirosis range from subclinical to potentially fatal manifestations. The disease manifests as biphasic illness, consisting initial leptospiraemic phase lasting for 3 to 7 days and an immune phase lasting for 4-30 days. On the basis of clinical features two forms of leptospirosis are described ie; anicteric and icteric leptospirosis.our patient presented with fever with chills,headache,vomiting,puffiness of face (because of vasculitis and capillary leak), pain abdomen, respiratory distress and cyanosis,This child was admitted to 2 different hospitals, but leptospirosis was not suspected because of nonspecific manifestations.

Figure - 1

X-ray chest revealed features of ARDS (figure 1). Severe respiratory system involvement leading to respiratory failure is very rare in anicteric leptospirosis.^[8] This patient had pulmonary alveolar hemorrhage leading to ARDS and expired 6 hours after admission. This child could have been saved if treatment was initiated early. Misdiagnosis and mismanagement is common for this potentially treatable condition.^[9]

Pulmonary manifestations occur in 20 to 70% of patients and many patients can progress to ARDS. ARDS is usually seen in second week of illness in severe form of leptospirosis. Our patient showed pulmonary involvement in the form of ARDS.V.Chouhan et al reported a case of severe leptospirosis involving acute renal failure, jaundice and pulmonary involvement.^[10] Severe form of leptospirosis including major hemorrhagic complications is usually associated with jaundice and renal failure.In a cohort of 26

Spanish patients 7 patients presented with hemoptysis and only 3 patients had ARDS.An ARDS requiring mechanical ventilation is associated with mortality rate as high as 30 to 60%.^[11]

Initial diagnosis of leptospirosis still remains a clinical presumptive one made in the correct epidemiological and clinical context. For early diagnosis,leptospira can directly be demonstrated in the blood by dark ground microscopy, however it is insensitive and shows false positive results. Culture of blood may be useful but requires specialized techniques.Detection of antibodies is the quickest way to confirm infection. Antibodies can be demonstrated by 5-6 days after the symptoms have developed.

The microscopic agglutination test (MAT) is accepted as the gold standard to detect genus specific antibody and it is available only in few reference centers.^[12] Lepto IgM ELISA detects the presence or absence of leptospira antibodies.it has a sensitivity of 97.29% and specificity of 99.84%. However it does not indicate the infecting serovar.Therefore the patient's clinical history, symptoms and absence of dengue antibodies the results of lepto IgM ELISA was considered in diagnosing leptospirosis.^[13] Leptospira IgM was detected by ELISA method in our case.

IgM class antibodies are detected starting as early as 5 days of onset of fever for early initiation of antimicrobial therapy for the potentially fatal disease. ELISA method is simple as compared with micro-agglutination test.^[11, 12] Leptospirosis responds to crystalline penicillin or doxycyclin. Prevention and

control measures includes, control of reservoirs like rodents, vaccination of animals Proper drainage system. Protection of people against contact with animal urine and health education regarding prevention of leptospirosis .Chemoprophylaxis for persons at risk like agricultural workers , sewage workers should receive doxycycline 200mg once a week for 6 months in endemic areas.

To conclude, Leptospirosis should be

strongly suspected in any febrile child during post monsoon.^[14,15] High index of suspicion is therefore needed in managing all cases of febrile illness in endemic areas of leptospirosis.^[16]

REFERENCES

1. Feign RD, Anderson DC. Leptospirosis. In Feign RD, Cherry JD, eds. Textbook of Infectious Diseases. Philadelphia; Saunders; 1998; 1529-1542
2. Farr P. W. Leptospirosis. Clin Infect Dis 1995; 21:1-8
3. Kuriakose M, Eapen CK, Paul R. Leptospirosis in Kolenchery, Kerala, India: epidemiology, prevalent local serogroups and serovars and a new serovar. Eur J Epidemiol 1997; 13:691-697
4. Muthusethupathi MA, Shivakumar S, Suguna R, Jayakumar M, Vijaykumar R, Everard COR et al. Leptospirosis in Madras- a clinical and serological study. J Assoc Physicians India 1995; 43:456-458
5. World health Organisation. Leptospirosis, India. Report of investigation of a post cyclone outbreak in Orrisa, November 1999. Wkly Epidemiol Rec 2000; 75:217-223
6. World Health Organisation. Guidelines for the control of Leptospirosis. In Faine S, ed. WHO Offset Publication No.67 Geneva: World Health Organisation, 1982; 1-171
7. Koutis Ch. Special Epidemiology. Editions, Technological Educational Institute of Athens. Athens, Greece 2007.
8. Ko A, Galvao Reis M, Riberio Dourado CM, Johnson WD, Riley LW and the Salvador Leptospirosis Study Group. Urban epidemic of severe leptospirosis in Brazil .Lancet 1999;