

Case Report

A Rare Presentation of Bilateral Papilledema in a Patient with Cerebral Arteriovenous Malformation

Donthi Krishnamurthy ¹, Narendra P Datti ¹, K Kanthamani ², Purnima Hegde ³

1. Professor, Department of Ophthalmology 2. Professor and HOD, Department of Ophthalmology

3. Professor and HOD, Department of Radio diagnosis. Sri Devaraj Urs Medical College, Kolar, Karnataka, India.

Abstract

A 40 year old lady presented with complete loss of vision in one eye and loss of perception of light in other eye since a year. Initially it was associated with constant headache without vomiting for around 3 months. Indirect ophthalmoscopy revealed chronic pale disc edema and dilated and severe tortuous blood vessels. MRI of the brain showed abnormal dilated tortuous vessels in the left temporal region communicating between basal vein and straight sinus. There was absence of flow voids in both sigmoid sinuses. MRI angiography revealed a small feeding artery to the right transverse sinus from posterior branch of middle meningeal artery. Findings suggestive of chronic raised Intra Cranial Tension were very evident. MRI and MRI angiography revealed a rare occurrence of dural arteriovenous malformation with isolated ocular symptoms and thus cerebral AV malformations with bilateral post papilloedemic optic atrophy was diagnosed.

Key-words: Papilloedema, Cerebral AV malformation, Optic atrophy, Dural AV Malformation (DAVM)

Introduction

Dural arteriovenous malformations (DAVM's) are rare vascular abnormalities comprising of numerous tiny connections between branches of dural arteries and veins or venous sinuses.^[1] Patient's with DAVM's may be completely asymptomatic or symptoms when present, may be mild or manifest as fatal hemorrhage which depend on location and drainage of the DAVM's. Dural fistulas produce intracranial hypertension which is associated with poor long term prognosis and may often present with headache, cranial neuropathies and visual deficits. We report an unusual case of long standing intracranial hypertension (ICT) secondary to DAVM's presenting as an isolated, profound bilateral visual loss which initially simulated inflammatory optic neuropathy.

Case History

A 40 year old woman presented with a gradual painless loss of vision in both the eyes for evaluation to the ophthalmology department at a medical college teaching hospital in Kolar. The poor vision for the past three years was initially associated with constant headache without any vomiting for about three months. She had consulted health care providers in her village for almost a year and a half. Later an eye specialist was consulted but she did not follow the advice given as the investigations were expensive. She also took medicines of alternative systems and did not find it useful for recovery of her vision. She gave no significant history of trauma or pain in the eyes. Her visual acuity was perception of light in right eye and no light perception with non-reactive pupils in left eye. Evaluation by ophthalmoscopy revealed chronic pale disc edema with dilated and severe tortuous blood vessels throughout the fundus (Fig 1).

In the background of long standing severe visual loss and disc edema, MRI was performed to rule out space occupying lesions

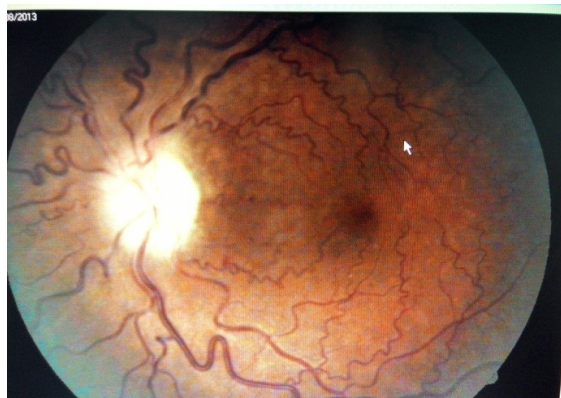
*Corresponding Author

Dr. D. Krishnamurthy,
Professor, Department of Ophthalmology,
Sri Devaraj Urs Medical College, Kolar, 563101.
Karnataka, India. E- mail: donthidkm@rediffmail.com
Received 25th Feb 2015, Accepted 24th Jun 2015.

causing chronic raised ICT and showed abnormally dilated tortuous vessels in the left temporal region communicating between basal vein and straight sinus posteriorly with dilated cortical veins (Fig 2).

MR angiography (Fig 3) and MR venography (Fig 4) revealed, AV malformation in the right occipital region with feeding vessel from branch of middle meningeal artery and draining into the sigmoid sinus; AV malformation in right temporo-parietal region draining into the superior sagittal sinus with feeding vessel from branches of middle cerebral artery; and AV malformation in left parietal region with branches from middle cerebral artery and draining into cortical vein on the left side. Findings suggestive of chronic raised ICT were evident such as empty sella, tonsillar herniation and dilated CSF space around optic nerves (Fig 3 & 4). With a diagnosis of intracranial posteriorly draining dural fistula, patient was referred to interventional radiologist for necessary management.

Fig 1. Fundus showing chronic pale disc with oedema and tortuous blood vessels of left eye



Discussion

DAVM's at various locations has been reported in literature with an incidence of 50% in transverse sinus, 16% in cavernous sinus, 12% in tentorium cerebelli and 8% in superior sagittal sinus.^[2] Middle meningeal dural arteriovenous malformations (MMAVM) are uncommon lesions secondary to trauma, surgery or endovascular procedures.^[3-5] The fistula can communicate with the accompany-

ing middle meningeal vein, diploic vein, adjacent cavernous, sphenoparietal, greater petrosal dural venous sinuses or into cortical vein.^[6-9] Cognard et al, studied 13 patients of DAVM's and noted varied clinical manifestations like headache, tinnitus, transient visual obscuration, diplopia secondary to sixth cranial nerve palsy and seizures.^[10] MMA fistula in the present case appears to be draining posteriorly into transverse sinus with absence of flow voids and dilated cortical veins.

Chronic ICT can be due to venous hypertension because of abnormal flows. These abnormalities were totally asymptomatic in the present case except for gradual painless loss of vision. As the fistula was draining posteriorly, no congestive symptoms were evident in the eye or orbit which made the diagnosis more difficult. Lumbar puncture is of considerable interest in the exploration of isolated intracranial hypertension, but may be very dangerous in the presence of dural fistula. Thus, before performing a lumbar puncture in patients with isolated intracranial hypertension, attempts should be made to exclude existence of a dural fistula.

The lesson is to be aware of possibility of dural fistula in a patient with isolated intracranial hypertension. Perhaps in the present case the only presentation was progressive visual loss which left no clue for the diagnosis initially.

Fig 2. Axial MR image showing multiple dilated veins in bilateral temporo-parietal regions.

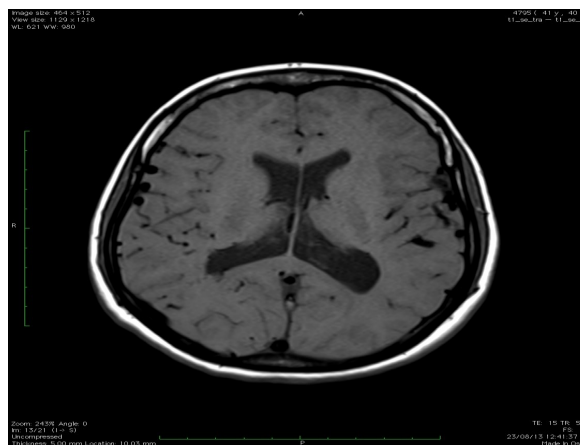

Fig 4. MR Angiogram image showing the right occipital AV malformation (white arrow) with feeding vessel from right middle meningeal artery draining into the sigmoid sinus and right temporo-parietal AV malformation (black arrow) with feeding vessels from branches of middle cerebral artery draining into superior sagittal sinus.

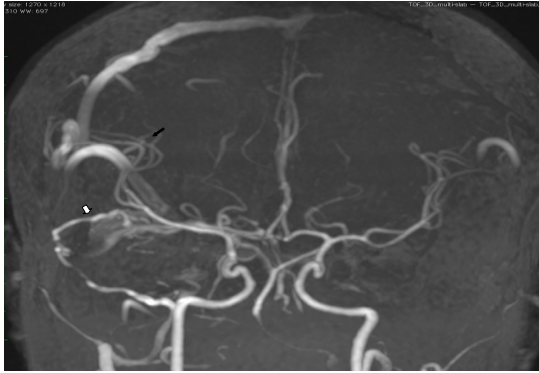


Fig 5. MR angiogram showing vascular malformations in right occipital region with feeding vessels from branch of middle meningeal artery and draining into right lateral sinus.

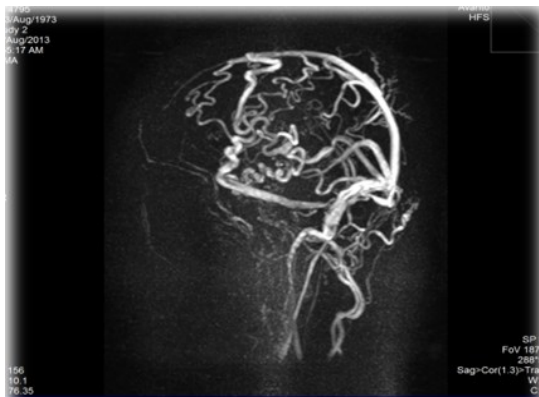
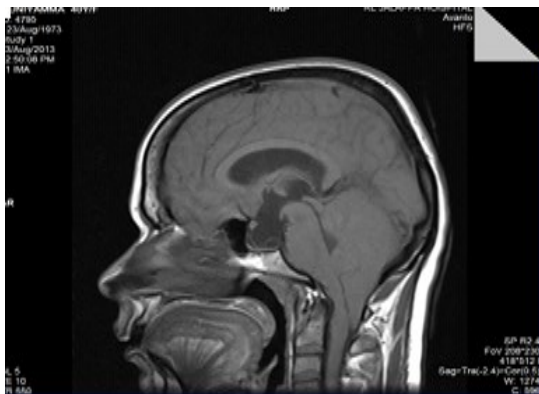

Fig 6. Sagittal MRI showing tonsillar herniation and empty sella.



Conclusion

Isolated presentation of profound visual deficit without any other signs of focal neurological deficit / ocular motor neuropathies made us to think of inflammatory or ischaemic optic neuropathies. Unusual findings in MRI followed by MRI angiography revealed rare occurrence of dural DVAM's with isolated symptom for which the case is reported.

References

1. Gupta AK, Periakaruppan AL. Intracranial dural arteriovenous fistula: A review. *Indian J Radiol Imag* 2009 ; 19(1): 43-8.
2. Lasjaunias P, Chiu M, TerBrugge K, Tolia A, Hurth M, Bernstein M. Neurological manifestations of intracranial dural arteriovenous malformations. *J Neurosurg* 1986; 64: 724-30.
3. Berenstein A, Lasjaunias P, Ter Brugge KG. Surgical Neuroangiography. Clinical and endovascular treatment aspects in adults Vol. 2, 2nd edition, Springer-Verlag, Berlin Heidelberg, 2002.
4. Freckmann N, Sartor K, Herrmann HD. Traumatic arteriovenous fistulae of the middle meningeal artery and neighbouring veins or dural sinuses. *Acta Neurochir (Wien)*1981; 55 (3-4): 273-81.
5. Terada T, Nakai E, Tsumoto T, Itakura T, Iatrogenic arteriovenous fistula of the middle meningeal artery caused during embolization for meningioma - case report. *Neurologia Medico Chirurgica* 1997; 37:677-80.
6. Fincher EF. Arteriovenous fistula between the middle meningeal artery and the greater petro sal sinus; case report. *Ann Surg.* 1951; 133(6): 886-88.
7. Castaigne P, Bories J. Meningeal arterio-venous fistulas with cortical venous drainage. *Rev Neurol.* 1976; 132(3): 169-81
8. James E. Smith, Joe Epps, Harry C. Press, Jr, and Luther B. Adair. Traumatic arteriovenous fistula between the middle meningeal artery and the sphenoparietal sinus: a case report and review of the world literature. *J Natl Med Assoc.* 1981; 73(3): 274-78.
9. Betz H. Traumatic arteriovenous fistula between the middle meningeal artery and vein. Spontaneous regression trend during angiographic controls. *Radiologie.*1974; 14(12): 528-31.
10. Christophe Cognard, Alfredo Casasco, Metin Toevi, Emmanuel Houdart, Jacques Chiras, Jean-Jacques Merland. Dural arteriovenous fistulas as a cause of intracranial hypertension due to impairment of cranial venous outflow. *J Neurol Neurosurg Psychiatry* 1998; 65:308-16.