

## Letter to the Editor

# Interesting Observation: Intramuscular Injection of Histoglobulins alleviated the symptoms of compromised Left Ventricular Ejection Fraction

## Abstract

Heart failure is a global pandemic with huge economic burden on developing countries like India. Aetiology is attributed to various factors and causes. Most common causes are pre-existing acute coronary syndrome and cardiomyopathy. The treatment to this disease is multi strategic. This case is reported to throw a light on a possible treatment to heart failure by introducing intramuscular histoglobulins along with the regular course of treatment.

**Key-words:** Heart Failure, Ejection fraction, Intramuscular histoglobulin

## Introduction

Heart failure is a global economic burden to the healthcare industry. Heart failure is characterized by reduced left ventricular (L V ) function leading to altered hemodynamics. The signs of left ventricular dysfunction (LVD) are neck vein distension, pedal edema, elevated jugular venous pressure, chest congestion. Patients would present with paroxysmal nocturnal dyspnoea, reduced work efficiency, effort tolerance. There would be an overall compromise in quality of life of the patient.

## Case History

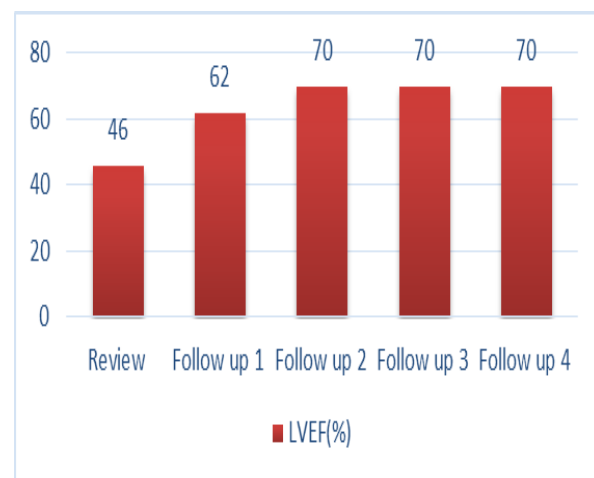
A 78 year old lady, weighing 78 kgs with diabetes mellitus, hypertension and coronary artery disease (Old anterior wall myocardial infarction) presented to the clinic with NYHA Class III symptoms such as breathlessness and fatigue. An echocardiogram was advised which revealed anterior wall hypokinesia with increased LV dimensions and impaired LVD (Ejection Fraction-46%). She treated with diuretics and anti congestive therapy along with antihypertensive and antidiabetic medications. Along with this she was administered intramuscular injection of histoglob 2ml once every week for one month and subsequently once every 15 days for the next two months and was followed up with an echocardiogram.

## Discussion

The patients first follow up (after 3 months) echocardiogram showed remarkable improvement in left ventricular ejection fraction (62%), with reduction of weight to 74 kgs and NYHA class I symptoms. The dosage was recommend-

ed 2ml for 15 days and was followed up after 6 months showed an improvement in ejection fraction (76%) and no symptoms. The dosage of injection histoglob remained same. The next review scheduled after 1 year also showed a good left ventricular function(74%) with no symptoms. We lastly followed up the patient on 10<sup>th</sup> November 2014 with an echocardiogram which showed good left ventricular function.

**Fig 1.** A Graph showing an improvement in Left ventricular Ejection Fraction (LVEF)



## Conclusion

We conclude that this drug might initiate calcium ion recycling by regulating SERCA2 and phospholamban proteins. This would enhance the strength of the myocardium contraction and establish the reversal of failure.

**References**

1. MuthuPeriaswamy and Sabine Huke "SERCA Pump Level is a Critical Determinant of Ca<sup>2+</sup> Homeostasis and Cardiac Contractility" *J Mol Cell Cardiol* 33: 1053–1063 (2001)
2. Kimberley.N.Gregory and Evangelia.G.Kranias "Targeting Sarcoplasmic Reticulum Calcium Handling Proteins as Therapy for Cardiac Disease" *Hellenic J Cardiol* 47: 132-143(2006)

**Dr.Ramesh Naidu Yadla, Mr.Varun Moganti**

Dept of Internal Medicine,

King George Hospital Visakhapatnam

Correspondence:Dr.Ramesh Naidu

E-mail address : rameshnaidu@gmail.com