

Case Report

Papillary Carcinoma in a Recurrent Thyroglossal Duct Cyst

Aparna Narasimha,¹ Udaya Kumar M,² Prathima S,³ Vasavi B,⁴ Bhaskaran A,⁵

1. Ex -Associate professor, 2. Ex -Professor, 3. Ex -Assistant Professor,

4. Post graduate student, Department of Pathology,

5. Professor, Department of Surgery, Sri Devaraj Urs Medical College, Kolar, Karnataka, India

Abstract

Thyroglossal duct cyst is the most common developmental abnormality encountered in the neck. Carcinoma arising in a thyroglossal duct cyst is a rare occurrence, and was first reported by Ucherman in 1910, the most common being papillary carcinoma. The incidence of primary papillary carcinoma arising in thyroglossal duct cyst is less than 1%. We report a case of papillary thyroid carcinoma occurring in a recurrent thyroglossal duct cyst in a 35 year old woman which was initially missed on fine needle aspiration cytology (FNAC), and subsequently diagnosed by histopathology. Though FNAC may aid in arriving at the diagnosis, it has limitations as in our case where carcinoma can be missed. Hence final pre-operative diagnosis should be combined with other diagnostic modalities.

Key-words: FNAC, thyroglossal duct cyst, papillary carcinoma, histopathology

Introduction

Thyroglossal duct cyst is a common congenital/developmental anomaly of the thyroid gland. This lesion though commonly encountered in children, can also be seen occasionally in adults. Though this anomaly is known to be associated with infections and sinus formation, but carcinoma occurring in this cyst is unusual. There are reported cases of carcinoma arising from the thyroglossal duct cyst, most common being papillary carcinoma.^[1] the first being reported by Ucherman in 1915, The incidence of primary papillary carcinoma arising in thyroglossal duct cyst is less than 1%.^[2] We report a case of papillary thyroid carcinoma arising in a recurrent thyroglossal duct cyst in a 35 year old female patient. Though the diagnosis of malignancy was initially missed on FNAC, we found an incidental occurrence of papillary carcinoma in a thyroglossal duct cyst on excision, without any involvement of the cervical lymph node or the thyroid gland.

Case History

A 35 year old woman complained of swelling in the midline of the neck in the submental region since the past five years. The swelling gradually increased in size since then and was associated with pain on pressure without any discharge. She had a history of undergoing a surgery at the same site 10 years ago and was diagnosed as a thyroglossal duct cyst.

On Examination

An oval swelling was observed in the submental region measuring 4X3 cm, firm in consistency, and mobile, with diffuse borders. Skin over the swelling showed a surgical scar. and no lymph nodes were palpable in the neck. An ultrasonogram (USG) of the neck revealed a thick walled multiseptate cystic mass with focal solid area with an impression of thyroglossal duct cyst. FNAC was performed and the aspiration yielded 0.1ml of brown colloid like material.

Cytological findings

Moderately cellular smears showed benign thyroid follicular cells arranged in monolayered sheets in singles and in clusters with mild anisonucleosis (Fig 1a). Background showed cyst macro-

*Corresponding Author

Dr. Aparna Narasimha
No. 22, Moyenville Road, Langford Town,
Bangalore-560025, Karnataka, India
E-mail: aparna_patho@yahoo.com
Received 5th May 2015, Accepted Sep 20th 2015

phages, thick colloid and erythrocytes. A single cluster of atypical cells with hyperchromatic nucleus and increased nuclear cytoplasmic ratio admixed with thick colloid were seen (Fig 1b). smears from repeated aspirations of the cyst did not reveal any atypical cells. Hence a diagnosis of colloid cyst was offered. In view of the position of the swelling a differential diagnosis of thyroglossal duct cyst was also considered. Surgical resection of the thyroglossal was preferred by Sistrunki procedure.

Gross findings

A skin covered soft tissue mass with hyoid bone, measuring 6x5x2 cm. was received. The cut section exuded yellow serous fluid and showed multiloculated cyst with smooth inner wall. Focal area showed papillary excrescence measuring 1.5 cm across (Fig 2a).

Microscopy

Sections showed cyst lined by non-keratinized stratified squamous epithelium. The lumen showed tumor tissue thrown into papillary folds (Fig 2b), at places showing follicular pattern lined by cuboidal epithelium (Fig 2c). The nucleus was optically clear (Orphan Annie nucleus), and a few showed nuclear grooving (Fig 2d). The cyst wall showed infiltration by the tumor. The hyoid bone and the skeletal muscle were uninvolved. A diagnosis of papillary carcinoma thyroid (follicular variant) arising in a recurrent thyroglossal duct cyst was conferred. Subsequent imaging of the neck showed no evidence of thyroid nodules or cervical lymph node enlargement. Patient underwent thyroid scintigraphy which showed normal uptake and was advised follow up.

Discussion

A thyroglossal duct cyst (TDC), an anomalous remnant of the thyroid gland development presents as a midline neck mass. The thyroid gland is connected to the base of the tongue through this duct during its descent, which in later stages involutes and disappears. Failure to involute results in its dilatation and formation of thyroglossal duct cyst. The incidence of ectopic thyroid tissue in a thyroglossal duct cyst varies from 1.5 to 45%.^[3] Clinically benign TDC presents as an asymptomatic, soft, firm or hard masses in the midline of the anterior neck, and are generally nontender and mobile.^[4] Carcinoma arising from thyroglossal duct cyst is very unusual and the usual age of its occurrence is 40 yrs with a slight female preponderance in the ratio of 3:2.^[2] A hard, fixed and irregular mass

which is progressively increasing in size, associated with enlarging cervical lymph node or any history of irradiation in childhood should raise the suspicion of malignancy.^[4] Similarly our patient who gave a history of a progressively increasing swelling in the midline of her neck. There are cases reported of occurrences of carcinoma arising from TDC in children also.^[4] Cytologically it may be difficult to distinguish between thyroglossal duct cyst and branchial cyst based on its anatomical site. Aspiration may yield mucin and ciliated/columnar epithelial cells may be seen. Thyroid follicular cells may rarely be seen in a branchial cyst. In a thyroglossal duct cyst, the aspirate is clear or mucoid fluid and squamous epithelial cells are seen. The aspirate is brown fluid in thyroid cysts or thick colloid in colloid nodules.^[5] The associate of the patient by FNAC yielded colloid like material and did not show any squamous epithelial cells. Hence we had to provide a differential diagnosis of colloid cyst along with thyroglossal duct cyst. This could be due to inadequate sampling as we may have not aspirated from the appropriate site or the lesion could have been too small for aspiration. As the cytological findings were correlated with USG findings, the clinician considered the diagnosis of a thyroglossal duct cyst and performed a Sistrunki surgical procedure. There are evidences proposing two origins for occurrence of malignancy in TDC: a) Thyrogenic carcinoma arising from thyroembryonic remnants in the duct or a cyst b) Squamous cell carcinoma arising from metaplastic columnar cells that line the duct.^[4] The presence of normal thyroid follicles in association with carcinomas in TDC suggests that the malignancy is arising primarily from the cysts, but the finding of neoplastic foci in thyroid gland represents its metastases to the TDC through its duct.^[6] Gebbia et al have reported a concurrent thyroglossal duct cyst carcinoma and thyroid carcinoma in a forty year old lady.^[7] Kandogan et al have reported papillary carcinoma arising in TDC with associated microcarcinoma of the thyroid without cervical lymph node metastasis.^[2] The different types of carcinoma arising from thyroglossal duct cyst include papillary carcinoma (85%), and squamous cell carcinoma (<5%), although follicular, Hurthle cell and anaplastic carcinoma have also been reported.^[5] Our patient has a follicular variant of papillary carcinoma. Many authors have reported papillary carcinoma to be the commonest tumor in TDC. It is hypothesized that cyst favours a papillary growth as seen in other cystic tumors like the ovarian tumors.^[8] Borger et al have reported a combined papillary and follicular carcinoma in TDC in a 12 – year old child.^[9] The diagnosis of carcinoma in a TDC is based on histopathological examination of the excised cyst. Hence along with FNAC, one

should employ other diagnostic modalities such as USG neck nuclear magnetic resonance (NMR) spectroscopy and computed tomography (CT) which may be helpful in making a pre-operative diagnosis of malignancy, and its spread and hence aid in accurate treatment strategies.^[7]

The main treatment for thyroglossal duct cyst is Sistrunk procedure which involves excision of TDC along with central portion of the body of hyoid bone and a core of tissue around thyroglossal tract to open into the oral cavity at the foramen cecum. Any surgical procedure which is short of the above can result in unacceptably high recurrence rates which is the most common complication as also seen in our patient.^[4] If malignancy is an incidental finding, then one should inspect the cervical lymph nodes and the thyroid gland, an extension of surgery must be handled according to the criteria established for differentiated thyroid cancer and post-operative radio-iodine therapy to be instituted if necessary.^[2] Such patients are to be followed up with thyroid scintiscan and serum thyroglobulin levels.^[5] The prognosis presents of variants TDC with papillary carcinoma is excellent and less favourable hila the squamous cell carcinoma.^[10]

Conclusion

Malignancy within a thyroglossal duct cyst though very rare should be considered in the differential diagnosis of a neck mass. Though FNAC may aid in arriving at a diagnosis, it has limitations as in our patient where carcinoma can be missed. Hence FNAC findings should be combined with other diagnostic modalities to arrive at a consensual diagnosis.

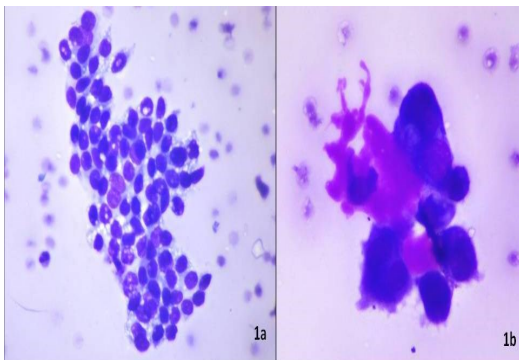


Fig 1. Microphotograph showing a) benign thyroid follicular cells arranged in monolayered sheets with mild anisonucleosis (MGG,X400) b) a single cluster of atypical cells with hyperchromatic nucleus and increased nuclear cytoplasmic ratio admixed with thick colloid (MGG,X1000).

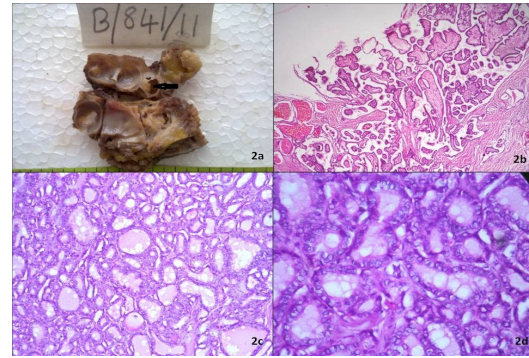


Fig 2. a) Gross photograph showing a multiloculated cyst with focal papillary excrescences (black arrow) b) lumen showed tumor tissue thrown into papillary folds (H&E,X40) c) tumor showing follicular pattern lined by cuboidal epithelium (H&E,X100) d) optically clear (Orphan Annie nucleus), a few showing nuclear grooving (H&E,X400).

References

1. Ambrosia A, Fersini A, Tartaglia N, De Fazio M, Cignarelli M, Neri V. Papillary carcinoma of the thyroglossal duct cyst: a case report. *G Chir* 2002; 23:129-33.
2. Kandogan T, Erkan N, Vardar E. Papillary carcinoma arising in a thyroglossal duct cyst with associated microcarcinoma of the thyroid and without cervical lymph node metastasis: a case report. *J Med Case Reports* 2008;2:42.
3. Allard RHB. The thyroglossal cyst. *Head Neck Surg* 1982;5:134-46.
4. Peretz A, Leiberman E, Kapelushnik J, HersHKovitz E. Thyroglossal duct carcinoma in children: Case presentation and review of the literature. *Thyroid* 2004;14:777-85.
5. Zivaljevic V, Bozic V. Papillary carcinoma in a thyroglossal duct cyst. *Acta chir belg* 2006;106:252-53.
6. Weiss SD, Orlich CC. Primary papillary carcinoma of a thyroglossal duct cyst: report of a case and literature review. *Br J Surg* 1991;78:87-89.
7. Gebbia V, Gregorio CD, Attard M. Thyroglossal duct cyst carcinoma with concurrent thyroid carcinoma: a case report. *Journal of Medical Case Reports* 2008;2:132.
8. Li Volsi VA, Perzin KH, Savetsky L. Carcinoma arising in median ectopic thyroid (including thyroglossal duct tissue). *Cancer* 1974;34:1303-15.

9. Borger JA, Bercu BB. Papillary-follicular carcinoma arising in a thyroglossal duct cyst in a 12-year old child. *Jr of Ped Surg* 1988;23:362-63.
10. Loree TR. Therapeutic implications of prognostic factors in differentiated carcinoma of the thyroid gland. *Semin Surg Oncol* 1995;11:246-55.
11. Ambrosia A, Fersini A, Tartaglia N, De Fazio M, Cignarelli M, Neri V. Papillary carcinoma of the thyroglossal duct cyst: a case report. *G Chir* 2002, 23:129-33.
12. Kandogan T, Erkan N, Vardar E. Papillary carcinoma arising in a thyroglossal duct cyst with associated microcarcinoma of the thyroid and without cervical lymph node metastasis: a case report. *J Med Case Reports* 2008;2:42.
13. Allard RHB. The thyroglossal cyst. *Head Neck Surg* 1982;5:134-46.
14. Peretz A, Leiberman E, Kapelushnik J, HersHKovitz E. Thyroglossal duct carcinoma in children: Case presentation and review of the literature. *Thyroid* 2004;14:777-85.
15. Zivaljevic V, Bozic V. Papillary carcinoma in a thyroglossal duct cyst. *Acta chir belg* 2006;106:252-53.
16. Weiss SD, Orlich CC. Primary papillary carcinoma of a thyroglossal duct cyst:report of a case and literature review. *Br J Surg* 1991;78:87-89.
17. Gebbia V, Gregorio CD, Attard M. Thyroglossal duct cyst carcinoma with concurrent thyroid carcinoma: a case report. *Journal of Medical Case Reports* 2008;2:132.
18. Li Volsi VA, Perzin KH, Savetsky L. Carcinoma arising in median ectopic thyroid (including thyroglossal duct tissue). *Cancer* 1974;34:1303-15.
19. Borger JA, Bercu BB. Papillary-follicular carcinoma arising in a thyroglossal duct cyst in a 12-year old child. *Jr of Ped Surg* 1988;23:362-63.
20. Loree TR. Therapeutic implications of prognostic factors in differentiated carcinoma of the thyroid gland. *Semin Surg Oncol* 1995;11:246-55.