

## Original Article

# Evaluation of Visual Outcome in Proliferative Diabetic Retinopathy After Panretinal Photocoagulation

Narendra Datti, Tanuja Abhilash, Balachandra<sup>1</sup>

Department of Ophthalmology and Medicine<sup>1</sup> Sri Devraj Urs Medical College, Kolar

### Abstract

**Objectives:** To evaluate maintenance of existing vision after pan retinal photocoagulation in type II diabetes with proliferative diabetic retinopathy and to assess the causes of severe visual loss after pan retinal photocoagulation (PRP).

**Materials and Methods:** 50 eyes of 28 patients with proliferative diabetic retinopathy (PDR) attending the retina clinic were included in this study. After detailed ocular examination and fundus fluorescein angiography, patients were treated with PRP. After PRP, visual acuity testing and retinal examination was done after 1 month, 3 months, 6 months and 1 year.

**Results:** At baseline 30% eyes had visual acuity of 6/6- 6/9, 44% had visual acuity of 6/12-6/36 and 26% eyes had visual acuity of <6/60. 73.3% of patients with visual acuity 6/6- 6/9 at baseline retained their vision, 26.67% had decreased vision. 86.36% of patients with visual acuity 6/12- 6/36 at baseline retained their vision, 9.09% had decreased vision and 4.55% of patients had improved vision. 92.30% with poor baseline visual acuity ( $\leq 6/60$ ) retained the same visual acuity and 7.69% of them improved to 6/9 at the end of 1 year. Causes of visual loss following PRP at the end of 1 year included vitreous hemorrhage (33.33%), pre retinal hemorrhage (33.33%), epiretinal membrane (33.33%), tractional retinal detachment (8.33%), macular edema (8%), choroidal effusion (8%), and acceleration of pre retinal fibrosis (8%).

**Conclusion:** After PRP, visual acuity was maintained at baseline in majority of patients. However, decreased vision seen in few patients occurred due to vitreous hemorrhage, pre retinal hemorrhage and macular edema.

**Key words:** Panretinal photocoagulation (PRP), Proliferative Diabetic Retinopathy (PDR), Early treatment diabetic retinopathy study (ETDRS), Fundus fluorescein angiography (FFA).

---

### Corresponding Author:

**Dr. Tanuja Abhilash**

Assistant Professor,,

Department of Ophthalmology

Sri Devaraj Urs Medical College,

Tamaka, Kolar - 56 3101 Ph: 9449979441

Email: tanuja.abhilash@gmail.com

### INTRODUCTION

Diabetic retinopathy remains a leading cause of visual disability in the developed world. At present diabetic retinopathy is projected to become a significant cause of blindness in the coming decade even in the developing countries.

In India it is estimated that the number of diabetics will rise from 19 million to 57 million between 1995 and 2025. Diabetic retinopathy is the leading cause for microvascular complications, among them vision impairment. Several studies indicate that 23% to 36% of all diabetics irrespective of the duration of the diabetes will develop diabetic retinopathy.

Photocoagulation still remains the most effective treatment for proliferative diabetic retinopathy. The beneficial effects of pan retinal photocoagulation (PRP) for diabetic retinopathy and its effectiveness in decreasing the incidence of blindness were established almost 20 years ago by Diabetic Retinopathy Study (DRS). The DRS study demonstrated that PRP reduces the risk of severe visual loss in high risk PDR by 50-60%. The Early Treatment Diabetic Retinopathy Study (ETDRS) showed that, vitreous or pre retinal hemorrhage was the major cause of visual loss following PRP.<sup>[1]</sup>

### **OBJECTIVES OF THE STUDY**

To evaluate maintenance of existing vision after PRP in patients with proliferative diabetic retinopathy and to evaluate causes of severe visual loss after PRP.

### **MATERIAL AND METHODS**

This prospective study was conducted at R. L. Jalappa Hospital and Research Centre, Sri Devaraj Urs Medical College, Kolar. During the above mentioned period, 28 randomly selected cases diagnosed with PDR attending retina clinic were included in this study. This study was done to evaluate the visual outcome after panretinal photocoagulation for proliferative diabetic

retinopathy.

### **INCLUSION CRITERIA**

1. Age 18 years and above.
2. Patients diagnosed with proliferative diabetic retinopathy with the following high risk characteristics will be included:

- Neovascularisation at the disc involving more than  $\frac{1}{3}$  to  $\frac{1}{2}$  disc area.

Or

- Neovascularisation at the disc and vitreous or pre-retinal hemorrhage.

Or

- Neovascularisation elsewhere involving more than  $\frac{1}{2}$  disc area and pre-retinal or vitreous hemorrhage.

### **EXCLUSION CRITERIA**

1. Patients with mild or moderate non proliferative diabetic retinopathy.
2. Patients with pre-proliferative diabetic retinopathy.
3. Major ocular surgery within past 6 months.
4. Patients for whom pan retinal photocoagulation was done within past 6 months.

Ocular parameters assessed included best corrected visual acuity using Snellen's visual acuity chart, intraocular pressure using Schiotz tonometer, slitlamp examination and retinal examination using direct ophthalmoscopy, indirect ophthalmoscopy, slit lamp biomicroscopy with 3 mirror lens and +90D lens. Fundus fluorescein angiography was done in all cases before laser therapy.

PRP was done using topical anesthesia for patients who fit into the high risk characteristic

criteria according to guidelines provided by ETDRS. A complete panretinal photocoagulation was performed with Iridex Oculight GL, frequency doubled diode pumped laser with wavelength 532 nm. A total number of 1600 - 2000 laser burns, using 300 - 500 spot size, for a duration of 0.1 seconds and power of 250 - 270mw was given in 2 to 3 sittings. The patients were followed up after 1 month, 3 month, 6 month, 1 year during which visual acuity was recorded and retinal examination was done. The following causes could be anticipated as reasons for diminished vision after PRP-chronic macular edema, pre-retinal fibrosis at macula, vitreous hemorrhage, extensive intra-retinal lesions (such as venous beading, blot hemorrhages). Such problems were recorded by fundus examination by direct ophthalmoscopy, indirect ophthalmoscopy, slit lamp biomicroscopy with +90 D lens. For those with persisting lesions, fundus fluorescein angiography was repeated and additional panretinal photocoagulation was given.

### **ANALYSIS OF RESULTS**

In this study visual outcome after panretinal photocoagulation was evaluated. Percentage of patients in whom baseline vision was maintained was noted. For those patients with decreased vision after PRP, the causes for decreased vision were analysed. The results of the visual acuity of the PRP and causes for decreased vision are presented as percentages.

### **RESULTS**

This was a prospective study done to evaluate visual outcome after PRP for PDR at R. L.

Jalappa Hospital & Research Centre attached to Sri Devaraj Urs Medical College, Kolar. Patients were followed up at 1 month, 3 months, 6 months and 1 year after laser treatment. A total of 50 eyes of 28 patients received PRP during the study period. Among the 28 patients 21 had bilateral PDR at baseline.

The mean age of the patients was 57.4 years. In our study, 8 patients were in the 40-50 age group, 23 patients in 51-60 age group, 13 in 61-70 age group and 6 patients were >70 years. There were 90% male eyes and 10% of female eyes. In these patients NVE was observed in 74% eyes and NVD in 26% eyes.

The average duration of diabetes of patients in our study was 11.06 years. In patients with <10 years of diabetes 76% subjects retained the same vision, 20% of eyes had decreased vision. In patients with 10-20 years of diabetes, 73% of patients had retained same vision and 30.4% had decreased vision (p value=0.35). This indicated that there is association of post PRP visual acuity with duration of diabetes. In our study the prevalence of complications was more in patients with duration of diabetes of more than 10 years but it did not show statistical significance. This is consistent with the guidelines shown in the ETDRS that when PRP is initiated early, visual prognosis is better. 74% of patients had associated hypertension which is a known risk factor for development of PDR. 64% of patients had associated family history which is another risk factor for development of PDR. Though the prevalence of hypertension and family history among those who had complications (p value=0.6 and 0.26 respectively) were more, it did not show

statistical significance in our study.

At baseline, 30% eyes had visual acuity of 6/6-6/9, 44% had visual acuity of 6/12-6/36 and 26% eyes had visual acuity of <6/60.

73.3% of patients with visual acuity of 6/6-6/9 at baseline retained their vision, 26.67% had decreased vision. 86.36% of patients with visual acuity 6/12-6/36 at their baseline retained their vision, 9.09% had decreased vision and in 4.55% vision improved. 92.30% with poor baseline visual acuity ( $\leq 6/60$ ) at baseline retained had the same visual acuity and 7.69% of them improved to 6/9 at the end of 1 year (Figure1).

Causes of visual loss following PRP at the end of 1 year included vitreous hemorrhage (33.33%), pre retinal hemorrhage (33.33%), epiretinal membrane (33.33%), tractional retinal detachment (8.33%), diabetic macular edema (8%), choroidal effusion (8%), acceleration of pre retinal fibrosis (8%) (Figure2).

## **DISCUSSION**

PRP in high risk PDR reduces the risk of severe visual loss by more than 50%. The present study attempted to evaluate the visual outcome of PRP. In a study done by Reema Mohan et al 73.2% of patients who had 6/9 or better vision at presentation maintained it at one year follow up compared to 14.3% of patients who had visual acuity less than 6/9 at baseline.<sup>[2]</sup>

Analysis of visual change after photocoagulation therapy in a retrospective study by Murat Dogru et al in 1998 revealed that 73% of the eyes with early PDR had stable vision or improvement by  $\geq 2$  lines at the end 10 year follow up visit.<sup>[6]</sup> The figures were 62% and 52% for eyes with advanced and end stage PDR

respectively.

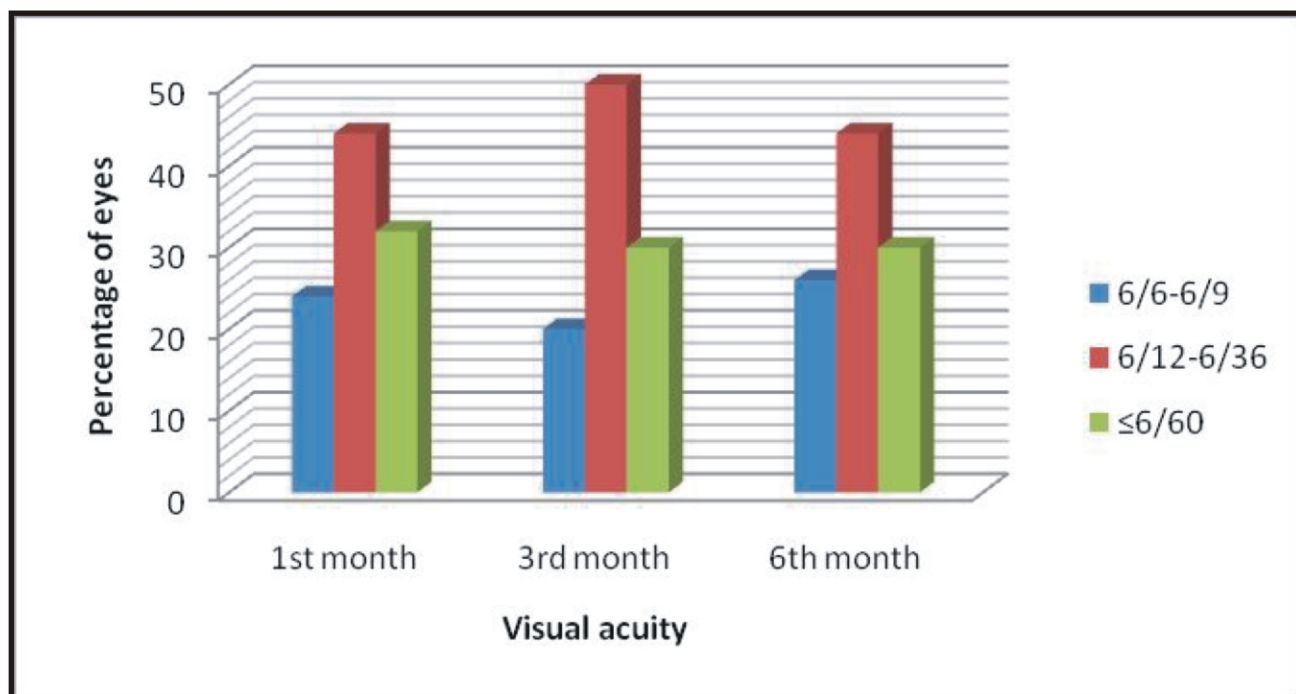
In a study by Qian Z et al proved that PRP was effective in 122 eyes (85.31%) out of 143 eyes.<sup>[7]</sup> Visual acuity improved in 32 eyes (23.38%), vision was maintained in 87 eyes (60.84%) and there was a decrease in 24 eyes (16.78%).

In our study by Richard S Kaiser et al 66% of eyes with poor visual acuity ( $\leq 20/200$ ) at baseline still had poor visual acuity at 1 year and 76% with good visual acuity ( $\geq 20/40$ ) at baseline maintained good visual acuity at one year.<sup>[5]</sup>

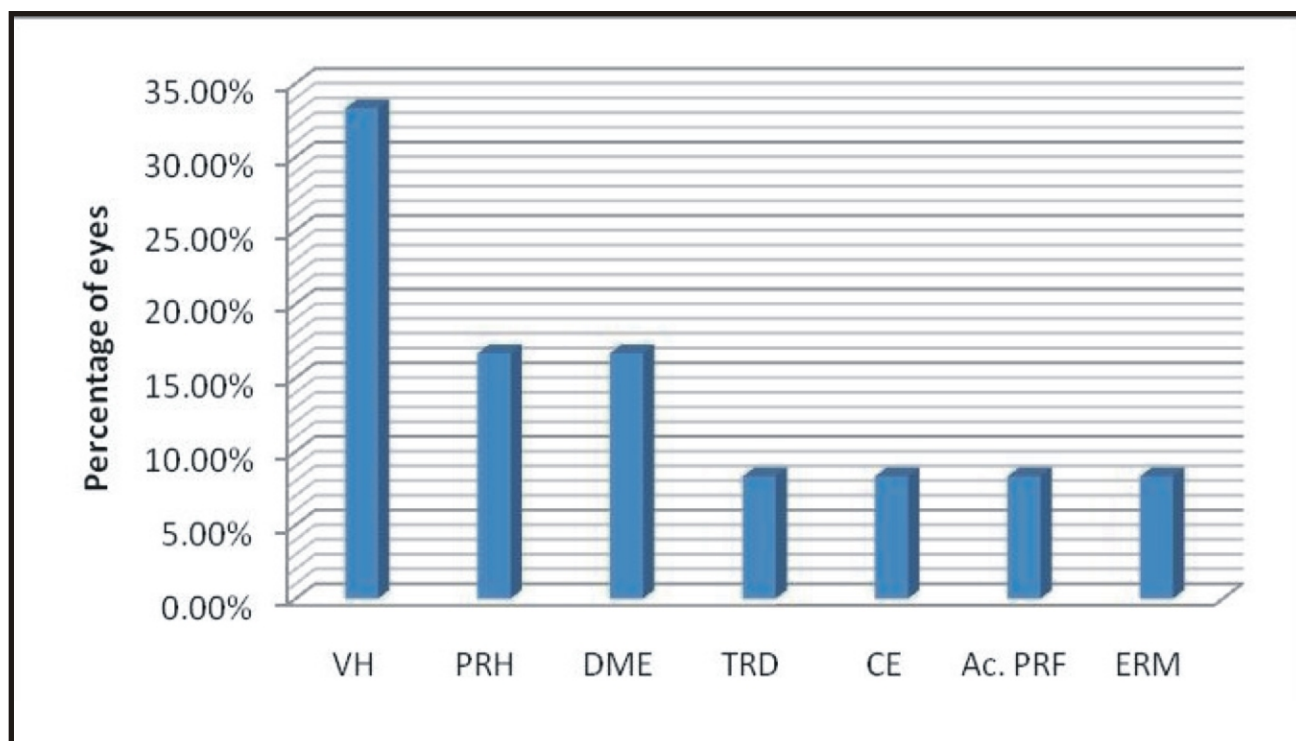
In our study vitreous hemorrhage was the most common cause of visual loss followed by preretinal hemorrhage, macular edema, choroidal effusion, tractional retinal detachment, epiretinal membrane and choroidal effusion.

Recurrence of retinal neovascularization was not identified in any of the patients. Late post laser hemorrhage indicates incomplete regression of neovascularization. Among the 4 patients who had vitreous hemorrhage, 1 patient underwent vitrectomy. Following surgery his vision improved to 6/9. 2 patients developed macular edema following PRP. This persistent macular edema developed as a side effect of PRP. Tractional retinal detachment involving the macula caused a drop in the vision of 3 lines.

Epiretinal membrane (ERM) which developed following PRP caused visual loss of 4 lines in 1 eye. The forces of vitreoretinal traction could have produced tangential traction on the ERM. Laser treatment stimulates contraction of this membrane, increases macular surface wrinkling and thereby reduces vision. Choroidal effusion developed in one patient and this could be because large numbers of burns were placed in



**Figure 1: Visual acuity at the end of 1st, 3rd and 6th month post PRP**



**Figure 2: Causes of severe visual loss post PRP**

**VH- Vitreous hemorrhage, PRH- Pre retinal hemorrhage, DME- Diabetic macular edema, TRD- Tractional retinal detachment, CE- Choroidal effusion, Ac.PRF- Acceleration of Pre retinal fibrosis, ERM- Epiretinal membrane**

one session.

A study done by Reema Mohan et al showed that causes of visual loss included vitreous hemorrhage in 20 subjects (31.7%), progression of cataract in 19 (30%), chronic macular edema in 15 eyes (23.8%), pre retinal hemorrhage in the macula in 6 (9.5%) and pre retinal fibrosis in the macula in 3 subjects (4.7%).<sup>[2]</sup>

In a study by Richard H et al the most common cause of decreased vision was chronic macular edema that had developed following laser treatment, occurring in 8% eyes.<sup>[4]</sup> The other causes of visual loss following PRP was vitreous hemorrhage (6%), tractional retinal detachment (3%), pre retinal hemorrhage (21%) and cataract (2%). Richard Kaiser et al showed that vitreous hemorrhage developed in 37% of eyes during the first year after panretinal photocoagulation and tractional retinal detachment developed in 6% of eyes at 1 year follow up.<sup>[5]</sup>

In a study by James F Vander et al showed that 6 of 59 eyes had vitreous hemorrhage following PRP for diabetic retinopathy.<sup>[3]</sup> Other causes of visual acuity showed diabetic maculopathy and cataract were other causes of subnormal visual acuity.

In a long term retrospective study Murat Dogru et al showed the main cause of severe visual impairment was progression of lens opacities in 25.6% of eyes, vitreous hemorrhage in 25% cases and macular edema in 7.7% patients. Other causes included macular traction and neovascular glaucoma.<sup>[6]</sup>

## CONCLUSION

In our study PRP has shown to induce regression of neovascularization and arrest of progression

of diabetic retinopathy. Also laser treatment is preferable to no treatment, but a timely applied treatment is more affective as far as visual prognosis is concerned. In our study 74.3% retained their baseline vision and decreased vision was noted in 22% of patients.

Laser treatment, if carried out properly rarely causes serious complications. In order to prevent the development of diabetic lesions in the eye, it is necessary to carry out regular ophthalmic checkup to qualify patients to laser treatment as early as possible.

## REFERENCES

1. The Diabetic Retinopathy Study Research group. Photocoagulation treatment of proliferative diabetic retinopathy: Clinical application of Diabetic Retinopathy Study. DRS report number 8. Ophthalmology 1981; 88:583-600
2. Rema M, Sujatha P, Pradeepa R. Visual outcomes of panretinal photocoagulation in diabetic retinopathy at one year follow up and associated risk factors. Indian J Ophthalmol 2005; 53:93-99
3. Vander JF, Duker JS, Benson WE, Brown GC, McNamara JA, Rosentein RB. Long term stability and visual outcome after favourable initial response of proliferative diabetic retinopathy to panretinal photocoagulation. Ophthalmology. 1991; 98:1575-9.
4. McDonald HR, Schatz H. Visual loss following panretinal photocoagulation for proliferative diabetic retinopathy. American Academy of Ophthalmology. 1985 march 1; 92(3):p.388-393.
5. Kaiser R, Maguire M, Grunwald J, Leib D,



Jani B, Brucker A. One-year outcomes of pan retinal photocoagulation in proliferative diabetic retinopathy. *Americal Journal of Ophthalmology*. 2000 ;( 129):178-85

6. Dogru M, Nakamura M, Inoue M, Yamamoto M. Long term visual outcome in proliferative diabetic retinopathy after panretinal

photocoagulation. *Japanese Journal of Ophthalmology*. 1999; 43:217-224

7. Qian Z, Zhu L, Zhao C. Observation on clinical effects of panretinal coagulation for diabetic retinopathy. *Yan Ke Xue Bao*. 2002 June; 18(2): 99-101.

<b>Source of Support: Nil    Conflict of Interest: Nil</b>
--