

Case Report

Incisional Endometriosis following Caesarean Section - A Case Report

Gomathy E¹, Ashritha R^{2*}, Deepika N³, Anil Sakalecha⁴

1. Professor 2. PG Resident 3. Assistant Professor, Department of Obstetrics and Gynaecology
4. Professor, Department of Radiodiagnosis, Sri Devaraj Urs Medical College, SDUAHER, Kolar, Karnataka, India.

Abstract

Scar endometriosis can be located at the skin, subcutaneously in the uterine scar and intraperitoneally. The incidence reported of abdominal scar endometriosis is 0.03 to 0.4%. Cyclical pain in the scar associated with the patients menstrual cycle is common. MRI is the most sensitive imaging method. Histopathological evaluation are confirmatory for the condition. Surgical excision of the scar is the treatment of choice. We report a case of caesarean section scar endometriosis treated at a medical college hospital.

Keywords: caesarean section, pregnancy, scar endometriosis.

Introduction

Endometriosis was first defined by Rokitansky in 1860 as the presence and proliferation of the endometrium outside the uterine cavity. It usually occurs in the pelvic sites such as ovaries, posterior cul-de-sac, uterine ligaments, pelvic peritoneum, bowel and rectovaginal septum. Extrapelvic endometriosis can be found in unusual places like nervous system, thorax, urinary tract, gastrointestinal tract and in cutaneous tissues.^[1] Incisional endometriosis/ scar endometriosis usually occurs in abdominal wall following surgeries especially early hysterectomy and caesarean section (Fig 1). The incidence of scar endometriosis following hysterectomy is 1.08-2.0% and after LSCS is 0.03- 0.4%.^[2] Its occurrence on the perineum, after episiotomy is still rare. Patients present with symptoms of pain and swelling at the incision site which become more prominent during menstrual periods.^[3,4] It is often misdiagnosed as stitch granuloma, keloid, haematoma, or an abscess.

Case Report

A 30 year old Para 5, living 3, dead 2 underwent lower section caesarean section 2 years back presented to gynecology out patient department with complaints of pain in caesarean scar site from 1 year. The pain aggravated during the menstrual periods. A firm and tender swelling of dark brown color measuring 2×2 cm was found at the left edge of the caesarean scar and was not fixed to the rectus sheath.

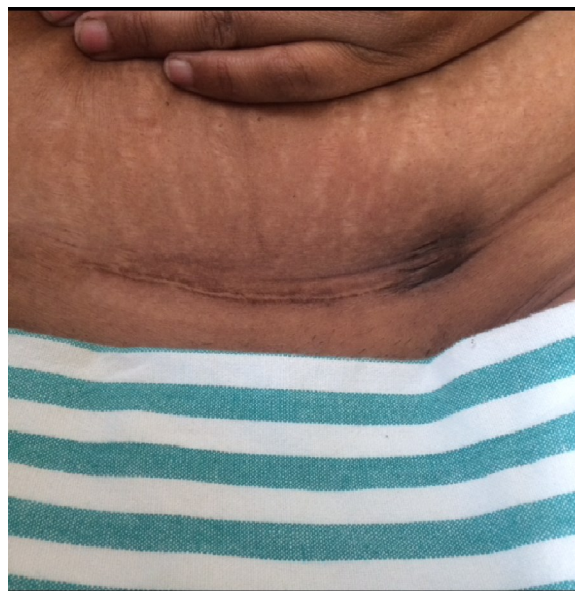

Fig 1. Caesarean Section scar

*Corresponding Author

Dr. Ashritha R,
PG Resident, Dept. of Obstetrics and Gynaecology,
Sri Devaraj Urs Medical College, SDUAHER, Kolar,
Karnataka, India.
E-mail: ashritrharhms@gmail.com
Received 22th July 2016, Accepted 20th Aug 2016

Sonography revealed a well defined hypo echoic lesion in the subcutaneous region beneath the abdominal external scar. Mild vascularity was noted on color Doppler. MRI revealed an oval lesion mildly hyper intense to muscle on T2 in the left lateral aspect of LSCS scar. Focal thinning of anterior myometrium was noted in mid segment of body of uterus with a linear cleft extending from endometrial cavity into myometrium (Fig 2).

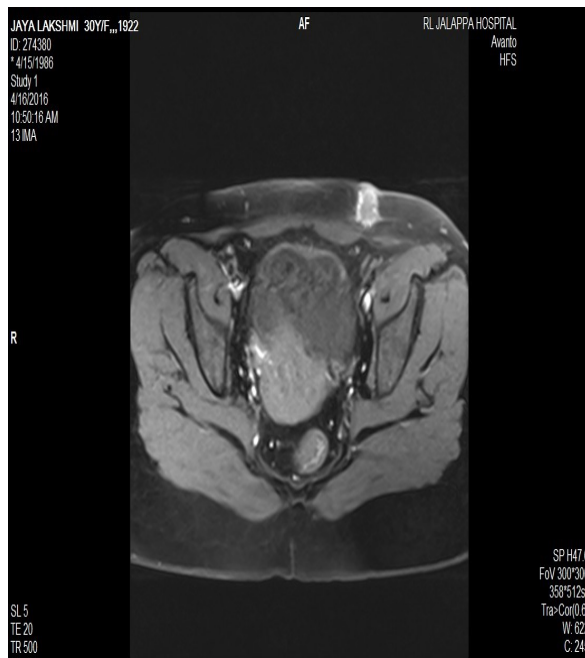

Fig 2. MRI image of the scar

A wide excision of the abdominal scar was performed under spinal anaesthesia. The excised scar was hard in consistency, reddish brown in colour and highly vascular. Scar endometriosis was confirmed by histopathological examination (Fig 3). There was no recurrence of the symptoms up to six months of out patient follow-up.

Discussion

Scar endometriosis on the abdominal wall is most commonly seen following surgeries on the uterus and the fallopian tubes. The endometrial tissue may be implanted in the scars during the surgical procedures and may proliferate on hormonal stimulation (cellular transport theory). The other explanation is that the neighborhood tissue may undergo

metaplasia which leads to scar endometriosis (coelomic metaplasia theory).^[5]

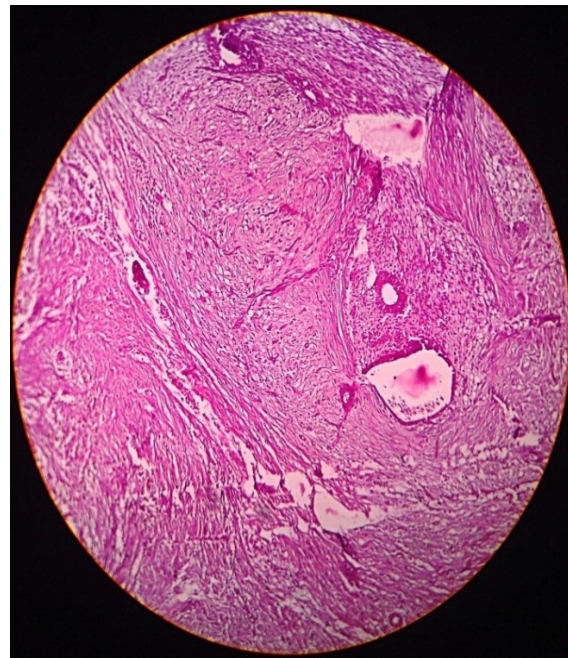


Fig 3. Histopathology of the scar showing endometriosis

The endometrial tissue may also reach the surgical scar through lymphatic and vascular routes. In a series of incisional endometriosis after caesarean section studied over 30 years, the incidence was found to be 0.08%. The average time from surgery to the clinical presentation of endometriosis varied from 3 months to 12 years in different case series.^[5] Presence of cyclic pain in an incisional mass is pathognomonic of scar endometriosis. MRI is considered more sensitive and also specific than sonography in the diagnosis of scar endometriosis.^[7]

The incidence of concomitant pelvic endometriosis with scar endometriosis has been reported to be from 14.3% to 26%. Ideally all patients must be examined for concomitant pelvic endometriosis.^[8] Histopathology is confirmatory. Wide local excision is the preferred treatment. Lesions extending deep to the muscles and fascia may require a synthetic mesh replacement or a tissue transfer for closure after resection. Recently usage of leuprolide depot has been found to be beneficial.^[6]

Conclusion

Scar endometriosis is a rare condition. It should be considered in the differential diagnosis in women presenting with painful symptoms with menstruation. The treatment of choice is surgical resection of the endometriosis with wide margins.

References

1. Khalifa Al- Jabri. Endometriosis at caesarean section scar. Oman Med J.2009;24:294-95.
2. Goel P, Sood S. caesarean scar endometriosis . JIMA, 2013; 7: 56-58.
3. Sudha. T, Anantha RP, Vani I, Subrahmanya SM. Scar endometriosis- A clinical rarity. IAIM, 2015; 2: 147-51.
4. Zararia AN, Goverdhan NA, Patil RT. Post caesarean scar endometriosis. JCR. 2015; 5: 401-05. Available from: <http://www.casereports.in/articles/5/2/Post-Caesarean-Scar-Endometriosis.html>
5. Minaglia S, Mishell DR Jr, Ballard C A. Incisional endometriosis after Cesarean section: A case series. J Reprod Med. 2007; 52: 630–34.
6. Rivilin ME, Das SK, Patel RB, Meeks GR. Leupride acetate in the management of cesarean scar endometriosis. Obstet & gynecol. 1995; 85: 838-39.
7. Jubanyik KJ, Committee F. Extrapelvic endometriosis. Obstetrics and gynecology clinics of north America. 1997; 24: 411- 40.
8. Gunes M, Kayikcioglu F, Ozturkoglu E, Haberal A. Incisional endometriosis after cesarean section, episiotomy and other gynecological procedures. Journal of obstetrics and gynecology research. 2005; 31: 471-75.