

Case Report

Extradural Neurilemmoma of The Lumbosacral Region

Bhaskaran A, Vasanthkumar G, Aparna Narsimha¹, Ambikavathy M,

Basavarajappa M, Harsha Kodliwadmth

Department of General Surgery and Pathology¹

Sri Devaraj Urs Medical College, Kolar, Karnataka

ABSTRACT

Neurilemmomas are benign encapsulated perineural tumors that originate from the Schwann cells of the neural sheath of motor and sensitive peripheral nerves. Paraspinal tumors present with great diagnostic dilemma and the exact nature of the lesion can only be defined after final histopathological examination. We present a case of extraspinal neurilemmoma with involvement of underlying fascia in the para spinal region which is a rare occurrence. Because of their locally "invasive" nature and extension in all directions, careful preoperative planning of the surgical approach is very important. In most cases radical resection is possible but recurrence may occur.

Keywords: *Neurilemmoma, schwannomma, extraspinal.*

INTRODUCTION

Neurilemmomas, also known as Schwannomas, are benign encapsulated perineural tumors of neuroectodermal derivation that originate from the Schwann cells of the neural sheath of motor and sensitive peripheral nerves. Schwannomas, together with meningiomas, are the most common intradural tumours. Over 70% of solitary lesions occur in either the head and neck or the extremities, and their presentation is usually that of an asymptomatic mass^[1]. Paraspinal tumors present with great diagnostic dilemma and the exact nature of the lesion can

only be defined after final histopathological examination. Because of their locally "invasive" nature and extension in all directions, careful preoperative planning of the surgical approach is very important ^[2]. We describe here a case of extraspinal neurilemmoma in the lumbosacral region in a middle aged lady.

CASE REPORT

A 45 year old lady presented with history of an otherwise asymptomatic swelling in the lumbosacral region for one year. Clinical examination revealed a globular swelling measuring 6x8 cms in the L₅S₁ region (Fig.1) which was non tender, firm, in the subcutaneous plane and fixed to the underlying muscle. No neurological deficits were evident on detailed neurological examination. Further evaluation was done in terms of fine needle aspiration cytology which was suggestive of

Corresponding Author:

Dr. Bhaskaran A

Professor & HOD,

Department of Surgery,

Sri Devaraj Urs Medical College,

Kolar-563 101,Karnataka, INDIA.

Mob: 9845045230

E-Mail: drbhaskara@in.com

neurilemmoma. MRI of the spine showed no extension to the spinal cord. The tumor was found to be adherent to erector spinae muscle & fascia. The patient underwent excision of the tumor along with the underlying adherent fascia (Fig 2a). No bony involvement was present. The post operative period was uneventful & the patient did not develop any neurological deficits post operatively. The histopathology of the excised specimen (Fig2b) confirmed the diagnosis of neurilemmoma (Fig 3a & 3b).

DISCUSSION

Spinal cord tumors can occur within or adjacent to the spinal cord. Primary spinal cord tumors account for 2 to 4 percent of all primary central nervous system (CNS) tumors, one-third of which are located in the intramedullary compartment. Spinal cord tumors can be classified according to their anatomic location.^[2] Intramedullary tumors arise within the spinal cord itself. Most primary intramedullary tumors are either ependymomas or astrocytomas.

Tumors arising within the dura but outside the actual spinal cord are termed intradural-extramedullary. The most common tumors in this group are meningiomas and nerve sheath tumors.

Extradural tumors are usually metastatic and most often arise in the vertebral bodies. Metastatic lesions can cause spinal cord compression either by epidural growth that result in extrinsic spinal cord or cauda equina compression or less frequently by intradural invasion.

Extramedullary intradural spinal tumors are rare. Less than 15% of all central nervous system

(CNS) tumors are spinal. Ninety percent of these patients are older than 20 years. Most of spinal tumors are extradural (50-55%) whereas 40-45% is intradural. Furthermore, 5% are intramedullary and 40% are extramedullary. Most common are Schwannomas (29%), followed by meningiomas (25%) and gliomas (22%)

Neurilemmomas are benign, encapsulated tumors of the peripheral nerve sheath. Their cells of origin are thought to be Schwann cells derived from the neural crest. The exact etiology is unknown. These masses usually arise from the side of a nerve, are well encapsulated, and have a unique histologic pattern. They form firm, well-circumscribed, encapsulated round, or ovoid tumors. The tumor is usually solitary, smooth-surfaced, slow growing, and generally asymptomatic, although tenderness or pain may occur in some instances. It may resemble a number of benign soft tissue lesions. The central lesion in bone may produce considerable destruction of bone with expansion of the cortical plates and thus resemble a more serious lesion. Pain and parasthesia are not uncommon for intrabony tumours.^[3]

Neurilemmoma can be associated with von Recklinghausen disease; when this is the case, multiple tumors are often present. No racial or sex predilection is recognized. Neurilemmomas affect persons aged 20-50 years. Common locations for the tumors are, in order of decreasing frequency, the head and flexor surfaces of the upper and lower extremities and the trunk. The mass is usually mobile in the transverse plane and tethered along the axis of the nerve from which it arises.

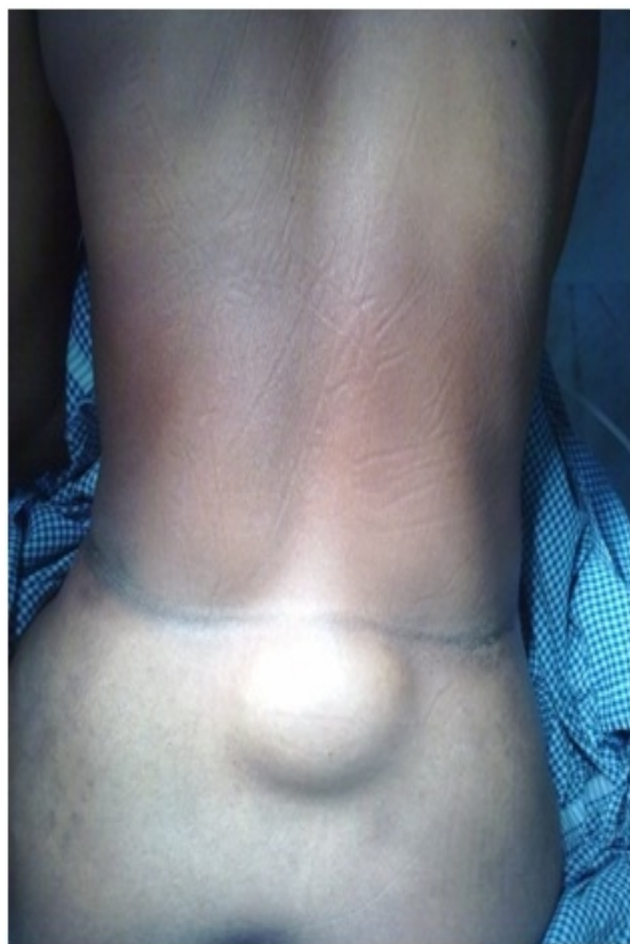

Fig.1- Lumbosacral swelling

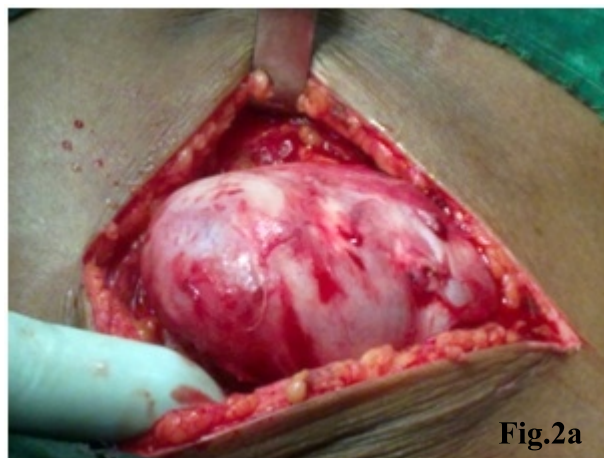


Fig.2a

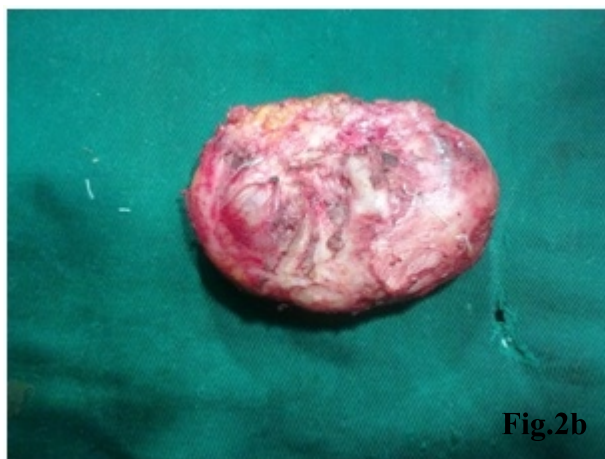


Fig.2b

**Fig.2- Gross Specimen (a) in situ
(b) excised**

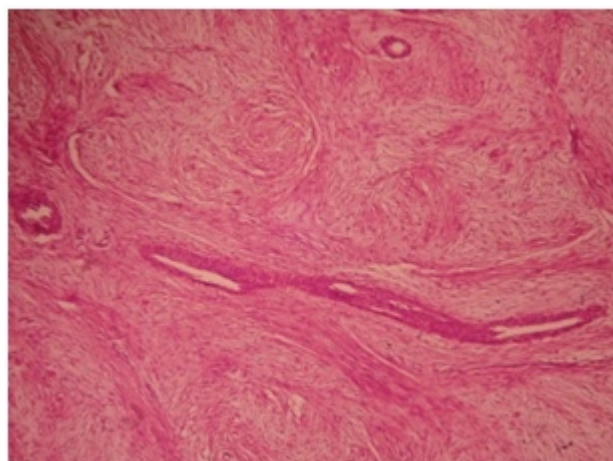


Fig.3a
Microphotograph showing hypercellular (Antoni A) and hypocellular (Antoni B) areas (H+E, x100)

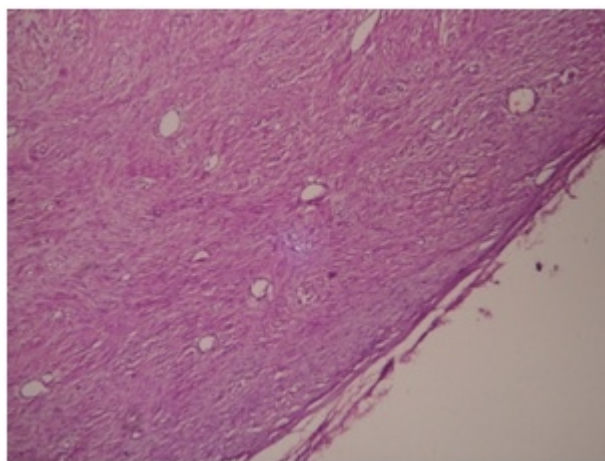


Fig.3b
Microphotograph of Neurilemmoma showing verocay bodies (H+E, x100)

Tenderness is often present; secondary neurologic symptoms may occur if the tumor is large. When involving the C7 nerve root, neurilemmoma has been described as a cause of thoracic outlet syndrome. Lesions in the sciatic nerve can mimic discogenic low-back pain. Neurilemmomas can cause a functional deficit because of local pressure on the nerve of origin. Malignant degeneration, which is extremely rare, has been described. Primary malignant tumors of this cell type do exist, but they are histologically distinct from neurilemmomas.^[4,5]

Laboratory studies generally are not beneficial. Plain radiograph findings generally are not specific. Special studies to consider are CT scan or MRI. MRI is particularly useful in getting the extent of the tumor and involvement of adjacent structures. Biopsy may be needed to clearly define the tissue type. For bone lesions and for particularly large soft tissue lesions, biopsy is prudent to ensure correct diagnosis and management.^[6]

Differential diagnosis include fibroma, neurofibroma, neurosarcoma, ganglion cyst, giant cell tumor of tendon sheath, or lipoma. Surgical excision is the treatment of choice in most lesions. In unusual cases in which resection would lead to a significant functional deficit, these benign lesions can be merely observed. In our case the lesion was adherent to the underlying fascia and was excised with the fascia involved by the tumor. In most cases radical resection is possible but recurrence may occur.^[3,7]

CONCLUSION

The purpose of presenting this case is to

emphasize on the precise preoperative localization of the tumor and its removal. The occurrence of this tumor in the paraspinal region is very uncommon. Neurilemmoma is a benign, encapsulated lesion occurring predominantly in the head, neck & trunk regions. It poses a diagnostic problem owing to its non specific clinical & radiological features. Biopsy is diagnostic in these cases. Malignant transformation is extremely rare. Surgical excision has remained the mainstay of treatment. Although radical excision is possible and promises good results, recurrences may occur and multiple surgical procedures may be required.

REFERENCES

1. A Jaiswal, AP Shetty, S Rajasekaran. Giant cystic intradural schwannoma in the lumbosacral region: a case report. *Journal of Orthopaedic Surgery* 2008; 16(1):102-6.
2. Sridhar K, Ramamurthi R, Vasudevan MC, Ramamurthi B. Giant invasive spinal schwannomas: definition and surgical management. *J Neurosurg.* 2001; 94 (2 Suppl):210-5.
3. Dickey DI, Gellman H, Floyd J. Neurilemmoma. *Medscape Reference*, Jan 2010.
4. Pandarakalam C, Sudha S, Shameena PM, Varghese VI. An unusual presentation of a case of schwannoma. *J Oral Maxillofac Pathol* 2005;9:27-29.
5. Takada E, Ozaki T, Kunisada T, Harada Y, Inoue H. Giant schwannoma of the back. *Arch Orthop Trauma Surg.* 2000;120(7-8):467-9.
6. GJayprakash, C Yong, W Yanqing A case

report of a Giant Schwannoma of the Mesorectum. BJMP 2009; 2(3) 51-53.

7. William CW, David S, Gerszten PC. Spinal

cord tumors. <http://www.uptodate.com> 19.2: May 2011.

Source of Support: Nil Conflict of Interest: Nil
--