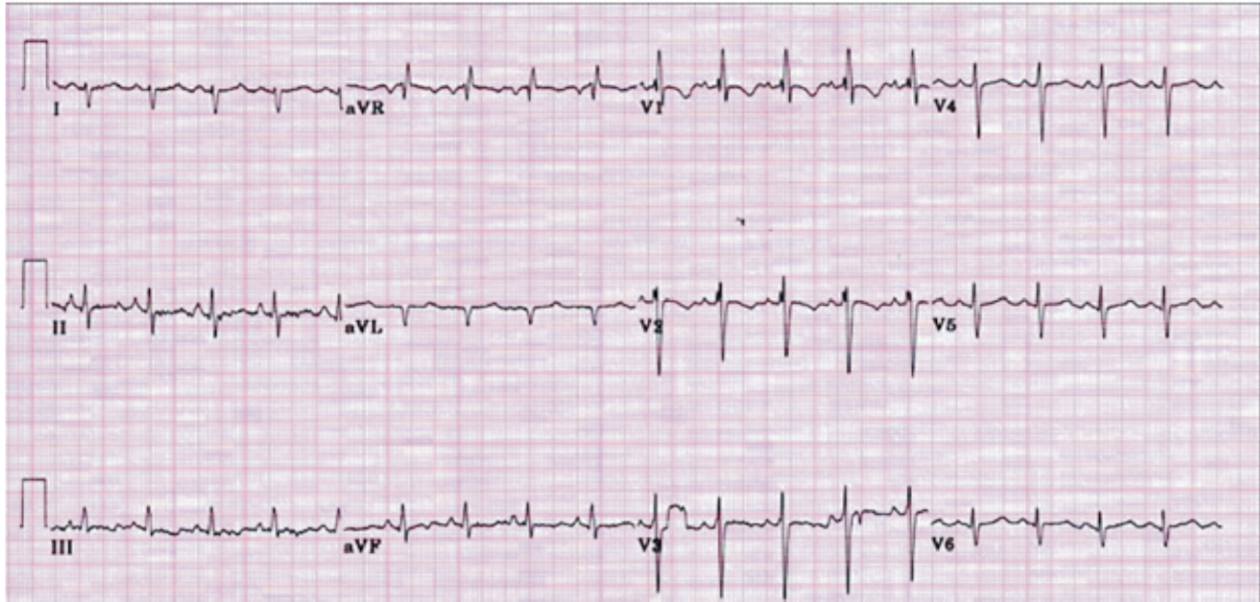


Quiz

ECG With No Prior Heart or Lung Disease

ECG in a 25 year male patient with right shoulder pain and history of alcohol abuse with no prior history of heart or lung disease



Q.1 What best explains all abnormalities in this ECG?

1. Sinus rhythm
2. Left atrial enlargement
3. Right atrial enlargement
4. Right ventricular hypertrophy
5. Left ventricular hypertrophy
6. All of the above
7. None of the above.

Q.2 Is this ECG helpful clinically in guiding further management?

1. Yes
2. No

Corresponding Author:

Dr. Venkatesh T.K.

Department of Medicine,
Sri Devaraj Urs Medical College,
Tamaka, Kolar - 563101, Karnataka, India.
Email: venkateshtekur@yahoo.com
Mobile No: 9844075579

Answer on page No. 49